



**Intacs**<sup>®</sup>  
CORNEAL IMPLANTS

**Intacs<sup>®</sup> Corneal Implants For the  
Treatment of Keratoconus**

*International Surgeon Training Manual*



155 Moffett Park Drive, Suite B-1 Sunnyvale, CA 94089-1330 U.S.A.  
[www.getintacs.com](http://www.getintacs.com)

MK-50222-01/Rev. B/02-07



**Intacs**<sup>®</sup>  
CORNEAL IMPLANTS

# International Surgeon Training Manual, Keratoconus



# Contents

- 1 Introduction to the Surgeon Training Program
- 2 History of Intacs Corneal Implants
- 3 Intacs Technology
  - 3.1 Intacs Corneal Implants - Keratoconus
  - 3.2 Intacs SK Corneal Implants - Severe Keratoconus
- 4 Patient Consultation, Selection and Preoperative Work-up
- 5 Preoperative Preparation: Instruments & Supplies, Patient Preparation, Medication and Infection Prevention
- 6 Intacs Corneal Implants Surgical Technique
- 7 Prevention & Management of Surgical Complications
- 8 Postoperative Care & Management
- 9 Intacs Corneal Implants Postoperative Findings & Classification System
- 10 Intacs Corneal Implants Removal and Replacement Procedure

---

Appendix A: Labeling

Appendix B: Technical Bulletins

# 1 Introduction to the Surgeon Training Program

# SURGEON TRAINING PROGRAM

## PURPOSE



## TRAINING REQUIREMENTS

To provide qualified surgeons with the information and skills necessary to select appropriate patients, perform competent surgery and manage possible complications related to the Intacs procedure for the treatment of keratoconus.

1. Successful completion of the on-line Intacs<sup>®</sup> Didactic Training Review course or a surgeon training course at an Addition Technology approved training program.
2. Successful completion of a Wet Lab with pig and/or human eye bank eyes.
3. Completion of first five surgeries under the observation of an Addition Technology designated proctor. **Every attempt should be made to schedule the initial surgeries on the same day.**
4. Review postoperative results from first five cases with Addition Technology designated proctor.

Upon successful completion of the training program, the Surgeon Training Record will be completed and signed by an Addition Technology representative and the surgeon. The Surgeon Training Record is sent to Addition Technology and the surgeon's name is then added to the list of those qualified to perform the procedure.

## MAINTENANCE OF TRAINING STATUS

As the procedure, product and instruments are updated, Addition Technology will continue to educate surgeons via seminars and direct visits from qualified Company representatives or their designees. To maintain status, a surgeon must be accessible to the Addition Technology representative for direct training and must attend future training seminars, as required. Critical training updates are documented with additional Surgeon Training Records, which are signed and sent to Addition Technology so the surgeon's training status will be accurately maintained. Additionally, surgeons are expected to maintain and update this training manual by promptly reading through and incorporating all revisions sent by Addition Technology.

## NON-MAINTENANCE OF STATUS

Surgeons who continue to order product, but have not maintained current training on the product, instrumentation and/or the procedure, will be advised of the need to update their training status. Addition Technology will alert these surgeons (or their staff) by phone and by letter. An Addition Technology representative will contact the surgeon to offer additional training, as necessary.

# 2 History of Intacs Corneal Implants

# HISTORY OF INTACS CORNEAL IMPLANTS

1978	Intacs Corneal Implants were originally developed as a 360° ring by Tulsa optometrist A.E. “Gene” Reynolds, O.D., who also invented the CorneaScope® (one of the first commercially available photokeratoscopes) in the late 1960s.
1980	Kera Associates created in Santa Clara, California, to further develop Dr. Reynolds’ “ring” concept as well as his topography technology.
1985	First preclinical studies conducted using Dr. Reynolds’ ring product.
1986	KeraVision, Inc. established in Santa Clara to focus exclusively on developing ICR® (Intrastromal Corneal Ring) technology. The company was relocated to Fremont, California, in 1994.
1988	Preclinical studies started in preparation for FDA-regulated clinical trials.
1991	Human clinical trials initiated with three nonsighted patients in Brazil and 10 Phase I nonsighted patients in the United States. First sighted-eye study with 10 myopic patients initiated in Brazil.
1993	U.S. Phase II myopia trial to evaluate the 360° ICR started in New York, St. Louis and Kansas City.
1994	A feasibility study on astigmatic patients was initiated in Brazil using core ICR technology.
1995	U.S. Phase II myopia trial to evaluate the ICRS® (Intrastromal Corneal Ring Segments) initiated. European myopia trial launched in France and U.K.
1996	U.S. FDA approval to proceed to Phase III clinical trial of the ICRS for the treatment of myopia (-1.00 to -3.50 D) in the U.S. European myopia trial initiated in Austria, France and Germany. CE Mark granted and first commercial sales realized under the trade name KeraVision Ring.
1997	U.S. Phase III enrollment of 360 patients completed. Preliminary hyperopia study begun in Mexico. U.S. Phase III trial expanded to correct myopia from -0.50 to -5.00 D.
1998	Health Protection Branch approval granted for commercial sale of the ICRS, under the trade name KeraVision Ring, for the correction of -1.00 to -5.00 D of myopia in Canada. By year’s end, over 1,700 eyes in worldwide clinical trials had received a KeraVision product for the correction of myopia.
1999	The trade name INTACS prescription inserts adopted for commercial sale of the ICRS for myopia. FDA approval granted for commercial sale of INTACS inserts for -1.00 to -3.00 D of myopia in the U.S.
2000	Myopia, myopia with astigmatism, and astigmatism studies initiated in Europe. Hyperopia study initiated in Europe.
2001	Addition Technology, Inc. acquired KeraVision assets in June.
2002	Addition Technology receives FDA approval for two intermediate INTACS inserts (0.275 mm and 0.325 mm). CE Mark granted for additional six INTACS inserts thicknesses (0.210 mm, 0.230 mm, 0.275 mm, 0.325 mm, 0.375 mm and 0.425 mm).
2003	CE Mark granted for treatment of keratoconus. Received Humanitarian Use Device (HUD) designation from FDA for keratoconus indication.
2004	Received Humanitarian Device Exemption (HDE) from FDA for keratoconus indication.
2005	The trade name Intacs Corneal Implants adopted for the myopia and keratoconus indications in the U.S. and international markets.
2007	Intacs SK Corneal Implants and Intacs SK Surgical Instruments for treatment of severe keratoconus added to CE Mark.

3 Intacs Technology

# *3.1* Intacs Corneal Implants - Keratoconus

# 3.1 INTACS CORNEAL IMPLANTS - KERATOCONUS

## 3.1

### DESIGN

Intacs® Corneal Implants are a new treatment option for patients who have keratoconus and are no longer able to achieve satisfactory vision correction with contact lenses or spectacles. When placed in the peripheral stroma at approximately two-thirds depth, outside the central optical zone, the product reshapes the anterior corneal surface while maintaining the positive asphericity of the cornea. Intacs Corneal Implants act as a structural element for support of the keratoconic cornea. Intacs Corneal Implants are designed to remain permanently within the cornea, however they can be removed or replaced, if desired.

The first-generation design of Intacs Corneal Implants was originally referred to as the 360° ICR® (Intrastromal Corneal Ring). The current design, Intacs Corneal Implants (also known as the KeraVision® Ring, ICRS® Intrastromal Corneal Ring Segments and INTACS® prescription inserts), consists of two clear, thin segments, each having an arc length of 150°. The product is referred to in this training manual by its brand name—Intacs Corneal Implants or Intacs segments.

Each Intacs segment has a hexagonal cross-section that lies along a conic section. With a fixed outer diameter of 8.1 mm and an inner diameter of 6.8 mm, Intacs segments have a large, clear central optic zone (Refer to diagram on page 3.1-8). Each segment has a small positioning hole located at each end of the segment to aid with surgical manipulation. The Intacs segments are placed equidistant on each side of the incision.

### MANUFACTURING & PACKAGING

Intacs Corneal Implants are manufactured from polymethylmethacrylate (PMMA) using techniques similar to those employed in intraocular lens (IOL) manufacturing. PMMA is the same polymer that has been used safely in IOLs for almost 50 years.

The product is provided sterile and nonpyrogenic. It is packaged inside a polycarbonate Intacs Carrier specifically designed to securely hold and protect the segments prior to placement. The Intacs Carrier is sealed inside a dual sterile barrier system consisting of inner and outer sealed plastic trays. Sterilization is achieved using ethylene oxide (EtO) gas. A unique lot number is specified on each Intacs Corneal Implants package and on additional labels contained inside—which are intended to be affixed to the patient’s identification card and medical records.

### HOW THEY WORK

Intacs Corneal Implants act as passive spacing elements that change the arc length of the anterior corneal curvature. The degree of corneal flattening or reduction of the cone achieved by the device is directly related to the thickness of the product. Placing the product in the periphery of the cornea causes local separation of the corneal lamellae that results in a shortening of the corneal arc length. This “shortening” of the corneal arc length has a net effect of flattening the cornea, thereby reducing and eliminating myopia and astigmatism in patients with keratoconus. When the thickness of the Intacs segments is increased, greater amounts of local separation occur that result in increased corneal flattening. Thus, the degree of corneal flattening—or correction—achieved by Intacs segments is directly related to thickness.

## 3.1 INTACS CORNEAL IMPLANTS - KERATOCONUS

# 3.1

The concept for the use of Intacs Corneal Implants to treat patients with keratoconus is that the Intacs segments provide a structural element to support the patient's bulging cornea, created by the thinning and abnormal keratoconic tissue.

The Intacs segments are placed within the cornea to lift the inferior or superior ectasia and to flatten the corneal tissue to decrease the asymmetric or irregular astigmatism that is induced by the keratoconus disease process and to address varying degrees of myopia.

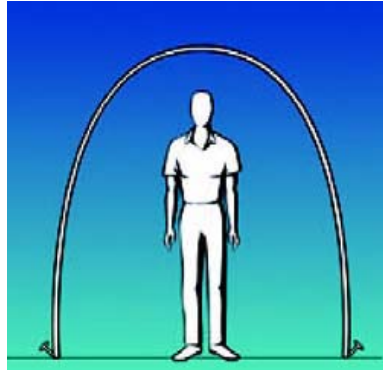Intacs Corneal Implants are intended to reshape the keratoconic cornea, by using two segments of either similar or different thicknesses, to create a more regular corneal surface. It is believed that the ability to create a more regularly shaped corneal surface and to possibly temporize the progression of the cone should allow the keratoconus patients to be successfully re-fitted with contact lenses, if required, to improve their functional vision and to potentially defer or eliminate the need for a corneal transplant procedure.

# 3.1 INTACS CORNEAL IMPLANTS - KERATOCONUS

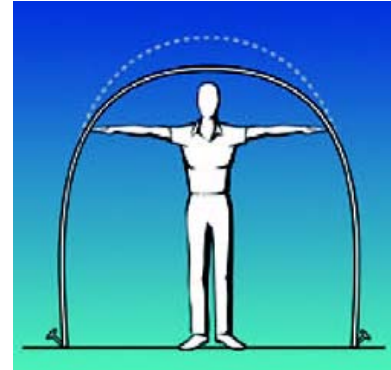
## 3.1

Imagine your cornea as a tent with a curved top. If you push out the sides of the tent, the top flattens. In much the same way, when Intacs Corneal Implants are placed within the stromal layers of the cornea, they shorten the arc length across the optical zone.

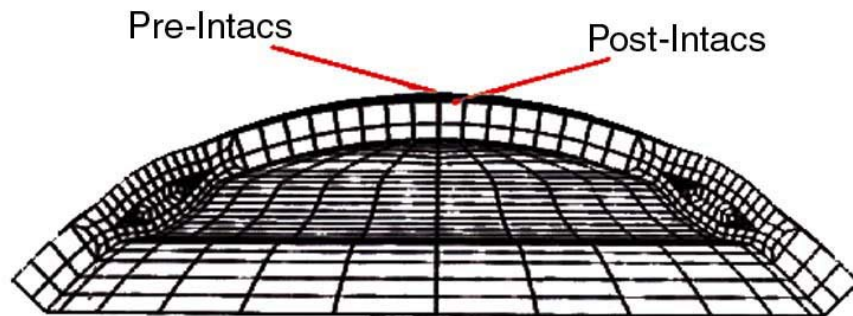
**BEFORE**



**AFTER**



This effect is further illustrated in the finite element model that follows.



A nearly linear relationship has been established between the device thickness and the flattening achieved for the treatment of myopia, with approximately an additional 0.70 diopter of flattening occurring for every 0.05 mm increase in device thickness.

# 3.1 INTACS CORNEAL IMPLANTS - KERATOCONUS

## 3.1 TREATMENT NOMOGRAM

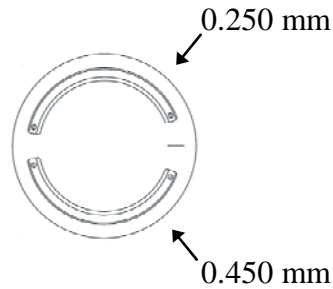
The Intacs Corneal Implants treatment nomograms for keratoconus are based on the use of the 0.250 mm, 0.300 mm, 0.350 mm, 0.400 mm and 0.450 mm thickness Intacs segments in clinical studies. Because each keratoconic patient's eyes and disease state are unique, determination of the specific Intacs product placement and the thickness of the Intacs segments to be implanted will vary from patient to patient. The determination of which thicknesses of Intacs segments to implant is dependent upon a number of variables; the most significant being the patient's preoperative manifest refraction spherical equivalent, the location of the cone and the degree of asymmetric astigmatism.

# 3.1 INTACS CORNEAL IMPLANTS - KERATOCONUS

## 3.1

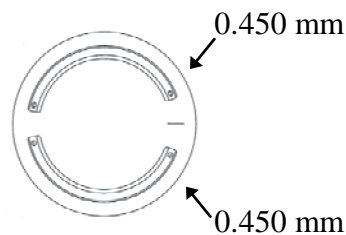
The three different product configurations recommended for the treatment of keratoconus are illustrated below.

**Diagram 1**



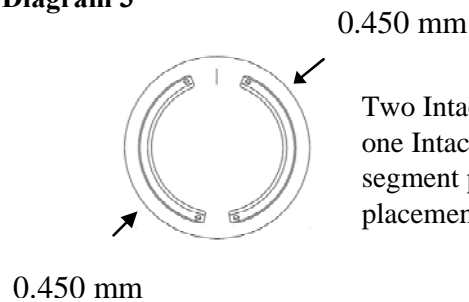
One thinner Intacs segment (e.g., 0.250 mm) placed superiorly and one thicker Intacs segment placed inferiorly (e.g., 0.450 mm), temporal incision placement (9:00 for right eye and 3:00 for left eye).

**Diagram 2**



Two Intacs segments of the same thickness – one Intacs segment placed superiorly and one Intacs segment placed inferiorly, temporal incision placement (9:00 for right eye and 3:00 for left eye).

**Diagram 3**



Two Intacs segments of the same thickness – one Intacs segment placed nasally and one Intacs segment placed temporally, 12:00 incision placement.

# 3.1 INTACS CORNEAL IMPLANTS - KERATOCONUS

# 3.1

**Recommended Intacs Corneal Implants Treatment Nomogram for Keratoconus**

Type of Keratoconus	Recommended Thickness Preop Spherical Equivalent ≤-3.00 D	Recommended Thickness Preop Spherical Equivalent >-3.00 D
Asymmetrical Cone		
Moderate Asymmetry	0.250 mm/0.300 mm 0.350 mm/0.400 mm	0.250 mm/0.350 mm 0.400 mm/0.450 mm
High Asymmetry	0.250 mm/0.400 mm	0.250 mm/0.450 mm
Global Cone/Central Cone	0.400 mm/0.400 mm	0.450 mm/0.450 mm

Six additional Intacs segment thicknesses (0.210 mm, 0.230 mm, 0.275 mm, 0.325 mm, 0.375 mm and 0.425 mm) were approved subsequent to the completion of the European Keratoconus Clinical Study. The six new thicknesses provide for lower levels and smaller increments of correction compared to the original five Intacs segment thicknesses and, as such, should allow for an increase in the number of treatment options available to the surgeon and keratoconic patient. The use of these additional thicknesses could potentially help to improve visual outcomes by virtue of the fact that surgeons will have a wider selection of Intacs Corneal Implants available to choose from to modify or adjust the cone.

With regard to the level of myopic correction to be achieved, surgeons should anticipate a “shift in the myopic spherical equivalent” equal to roughly half of the dioptric correction predicted for two Intacs segments implanted. For example, for a keratoconic patient implanted with two Intacs segments, one 0.350 mm and one 0.400 mm, the predicted shift in the myopic spherical equivalent would be equal to an average of the nominally predicted correction for the average of the two thicknesses, in this case, -3.05 diopters.

Example: 
$$\left[ \frac{(-2.70 \text{ D}) + (-3.40 \text{ D})}{2} \right] = -3.05 \text{ D}$$

# 3.1 INTACS CORNEAL IMPLANTS - KERATOCONUS

# 3.1

Based on laboratory and U.S. clinical trial results, a continuous but non-overlapping recommended prescribing range has been developed for each thickness, as shown below:

**Table 1: Intacs Corneal Implants Recommended Prescribing Range**

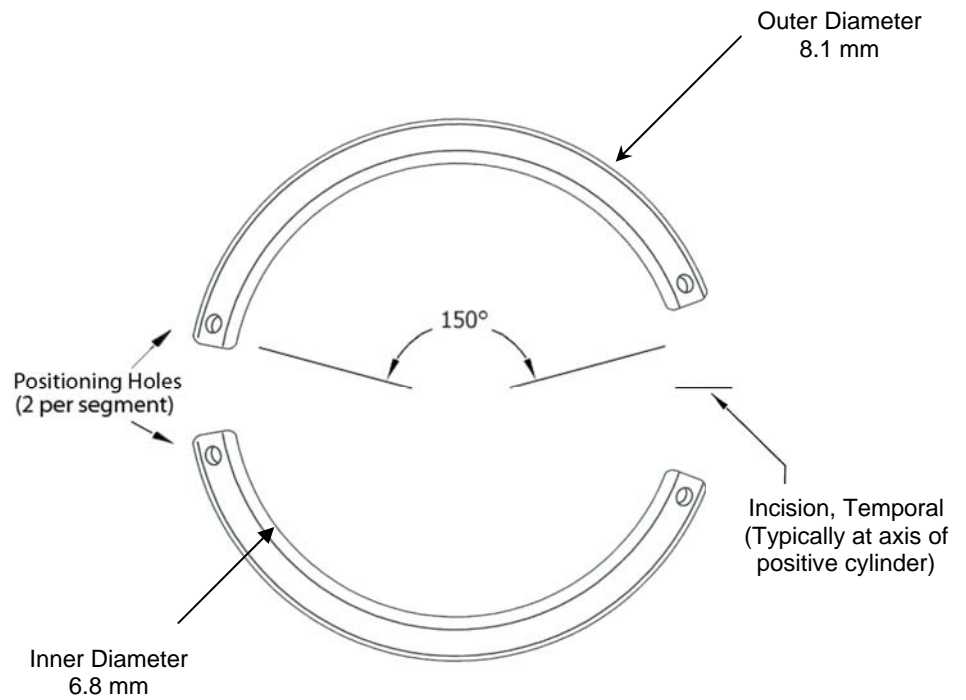
<b>Intacs Thickness</b>	<b>Predicted Nominal Correction</b>	<b>Recommended Prescribing Range</b>
0.210 mm	-0.75 D	-0.500 to -0.875 D
0.230 mm	-1.00 D	-1.000 to -1.125 D
0.250 mm	-1.30 D	-1.250 to -1.500 D
0.275 mm	-1.70 D	-1.625 to -1.750 D
0.300 mm	-2.00 D	-1.875 to -2.125 D
0.325 mm	-2.30 D	-2.250 to -2.500 D
0.350 mm	-2.70 D	-2.625 to -2.750 D
0.375 mm	-3.00 D	-2.875 to -3.125 D
0.400 mm	-3.40 D	-3.250 to -3.500 D
0.425 mm	-3.70 D	-3.625 to -3.875 D
0.450 mm	-4.10 D	-4.000 to -4.250 D

NOTE:

*Table 1 is intended as a guide only. The appropriate Intacs Corneal Implants thickness for a keratoconus patient will depend on several variables, including the patient's age, occupation, degree of desired correction, location of cone and degree of existing astigmatism.*

# 3.1 INTACS CORNEAL IMPLANTS - KERATOCONUS

# 3.1



**Diagram of Intacs Corneal Implants**

# 3.2 Intacs SK Corneal Implants - Severe Keratoconus

## 3.2 INTACS SK CORNEAL IMPLANTS - SEVERE KERATOCONUS

# 3.2

DESCRIPTION OF THE DEVICE

Intacs® SK Corneal Implants, are an ophthalmic medical device designed for the reduction or elimination of myopia and astigmatism in patients with severe keratoconus so that their functional vision may be restored and the need for a corneal transplant procedure can potentially be deferred. When placed in the corneal stroma, outside of the patient's central optical zone, the product reduces the cone by flattening the cornea. The Intacs SK segments are designed to be placed slightly outside of the central optical zone of the cornea, at approximately two-thirds depth, and are surgically inserted through a small radial incision in the corneal stroma. The Intacs SK product has been designed to allow removal or replacement.

The Intacs SK Corneal Implants are composed of two clear segments, each having an arc length of 150°. The Intacs SK Corneal Implants have a fixed outer diameter of 7.3 mm and an inner diameter of 6.0 mm (Refer to diagram on page 3.2-2). They are manufactured from polymethylmethacrylate (PMMA) and are currently available in two thicknesses: 0.400 mm and 0.450 mm. In order to reduce the myopia and the irregular astigmatism induced by keratoconus, two Intacs SK segments ranging from 0.400 mm to 0.450 mm may be implanted depending on the orientation of the cone and the amount of myopia and astigmatism to be reduced. The product is designed with a fixed outer diameter and width. Intacs SK Corneal Implants have a positioning hole located at each end of the segment to aid in surgical manipulation. The Intacs SK segments are designed with rounded edges to potentially reduce the incidence of visual symptoms since the SK segments are placed closer to the patient's central optical zone than the standard Intacs segments. Four new SK Surgical Instruments (SK Procedure Marker, SK Corneal Separator-Clockwise, SK Corneal Separator-Counterclockwise and SK Inspection Gauge) have also been developed to accommodate the new placement position in the cornea.

## 3.2 INTACS SK CORNEAL IMPLANTS - SEVERE KERATOCONUS

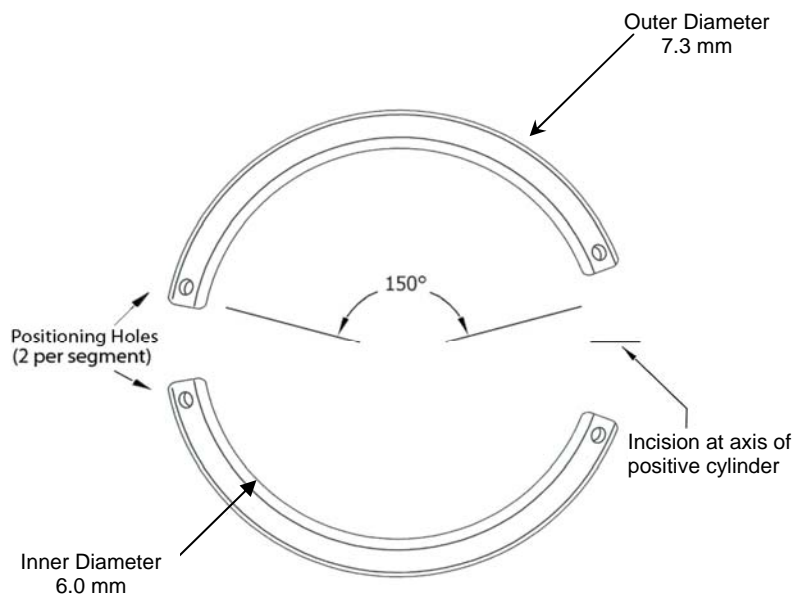
# 3.2

TREATMENT  
NOMOGRAM

Because each keratoconic patient's eyes and disease state are unique, determination of the specific Intacs SK product placement and the thickness of the Intacs SK segments to be implanted will vary from patient to patient. The determination of which thicknesses of the Intacs SK segments to implant is dependent upon a number of variables with the most significant being the patient's preoperative keratometry readings, the location of the cone and the degree of asymmetric astigmatism.

Intacs SK Corneal Implants have been designed to reduce myopia and irregular astigmatism induced by severe keratoconus. We recommend that two symmetric segments be implanted at the periphery of the patient's 6.0 mm optical zone, in accordance with the guidelines provided below. Typically if a patient has an average keratometry reading between 55-62 D, they should be implanted with the 0.400 mm Intacs SK segments. If a patient has an average keratometry reading greater than 62 D, they should be implanted with the 0.450 mm Intacs SK segments.

Keratometry Measurements	Intacs SK Thickness
55-62 D	0.400 mm
>62 D	0.450 mm



**Diagram of Intacs SK Corneal Implants**

## 3.2 INTACS SK CORNEAL IMPLANTS - SEVERE KERATOCONUS

### KEY TECHNICAL FEATURES OF INTACS SK CORNEAL IMPLANTS FOR SEVERE KERATOCONUS

- Designed for treatment of patients with severe keratoconus (keratometric readings of 55 D or greater)
- Available in two thicknesses: 0.400 mm and 0.450 mm
- Designed to be placed closer to the patient's central optical zone than the standard Intacs Corneal Implants
  - 6.0 mm inner diameter for Intacs SK product vs. 6.8 mm inner diameter for standard Intacs product
- Designed with rounded edges for reduction of visual symptoms
- Designed with a positioning hole at the end of each segment to aid in surgical manipulation
- Packaged in a green Carrier that is placed in a product carton with green labeling to differentiate the Intacs SK product from the standard Intacs product
- **Requires the use of four specially designed SK Surgical Instruments that will complement the standard Intacs® Prolate Surgical Instrument Set**

Note: The new SK Surgical Instruments have a smaller diameter to allow for the more central placement of the Intacs SK segments.

- SK Corneal Separators, CW & CCW (Model No. AT11209-1, 2)
- SK Inspection Gauge (Model No. AT11210)
- SK Procedure Marker (Model No. KV11211/AT11211)
- A new SK Sterilization Tray (Model No. 4710A) is available for use in sterilization and storage of the SK Surgical Instruments

## 3.2 INTACS SK CORNEAL IMPLANTS - SEVERE KERATOCONUS

# 3.2

### SURGICAL PROCEDURE

All other features of the Intacs SK Corneal Implants remain the same as the standard Intacs Corneal Implants, i.e., both are manufactured from polymethylmethacrylate (PMMA) material, both have a 150° arc length and both are provided as two segments placed inside the Carrier as part of the sterile package assembly.

The recommended Intacs SK procedure is provided in Chapter 6. **Please note the following changes for the Intacs SK surgical procedure only:**

- The SK Corneal Separators, CW & CCW will replace the standard Corneal Separators, CW & CCW, 0.9 mm
- The SK Inspection Gauge will replace the standard Inspection Gauge, 0.9 mm
- The SK Procedure Marker will replace the standard Procedure Marker, 0.9 mm

The remaining standard Intacs surgical instruments that are designated on the flow chart entitled, “Intacs SK Corneal Implants Surgical Procedure Flow Chart (10-Step Prolate System)” are to be used for completion of the Intacs SK surgical procedure.

# 4 Patient Consultation, Selection and Preoperative Work-up

# PATIENT CONSULTATION, SELECTION & PREOPERATIVE WORK-UP

## OVERVIEW

# 4

## WHAT IS THE CAUSE OF KERATOCONUS?

## TREATMENT OPTIONS

Keratoconus is a debilitating disease that causes progressive thinning and forward bulging of the cornea. This results in progressive distortion and a reduction in vision. Many keratoconus patients also experience blurred distance vision, astigmatism, glare, light sensitivity, disturbed night vision, headaches and reading problems. Keratoconus may affect only one eye but more commonly occurs in both eyes, however, the progression of the disease typically occurs at different rates for each eye. It affects people of all races and both sexes.

Patients who develop keratoconus often experience reduced vision as a first symptom. Nearsightedness and astigmatism are often the first signs of the disorder. Frequent prescription changes in an attempt to optimize the patient's vision are another common sign indicating the onset of keratoconus. Before computerized corneal topography became available, it was sometimes difficult to establish a diagnosis of keratoconus, especially if the physician was unfamiliar with the early-stages of the disease. Corneal topography has facilitated the diagnosis of keratoconus, helping to establish the diagnosis earlier, to follow the progression of the disease more accurately and to differentiate keratoconus from other degenerative corneal diseases.

No one really knows what causes keratoconus. We do know that keratoconus runs in families and that many patients who have keratoconus report vigorous eye rubbing. Many patients with keratoconus also have allergies, but the link to allergic disease also remains unclear. Two theories for keratoconus have been proposed:

- \* Keratoconic corneas are more easily damaged by minor trauma such as eye rubbing.
- \* Keratoconic corneas lack the ability to self-repair routine damage that is easily repaired by normal corneas.

Although long-term contact lens wear has been suggested as a possible cause of keratoconus, this has not been proven and remains questionable. Patients with keratoconus are advised to avoid eye rubbing as much as possible.

Refractive surgeons are firm believers in conservative treatment and minimizing risks to their patients. In the mildest form of keratoconus, eyeglasses or soft contact lenses often provide adequate vision. As the disorder progresses and the cornea becomes increasingly distorted, specially designed soft lenses often work well.

In more advanced stages of the disease, rigid gas permeable contact lenses are usually the best choice for visual rehabilitation. There are numerous contact lens designs used to treat keratoconus. Fitting contact lenses on a keratoconic cornea is a difficult and often time-consuming endeavor.

# PATIENT CONSULTATION, SELECTION & PREOPERATIVE WORK-UP

## 4

CONSULTATION  
WITH A  
PROSPECTIVE  
PATIENT

You can expect frequent return visits to fine-tune both the fit and prescription for the keratoconic patient. In some cases, the fitting process can take many months. For many patients the fitting process is a continuing process as the condition progresses.

Improperly fitted contact lenses can cause extensive damage to the cornea and can ultimately lead to a corneal transplant being required sooner rather than later. Contact lens fitters should be selected on the basis of experience and commitment to aiding keratoconus patients. Having a corneal topographer and several keratoconus contact lens trial sets available in the office are a positive sign for a good contact lens fitter.

Once your patient's cornea can no longer tolerate a rigid contact lens, or contact lenses no longer provide acceptable vision, the next step is surgery; either Intacs Corneal Implants or penetrating keratoplasty. Penetrating keratoplasty has proven to be a successful treatment option for those patients with late stage keratoconus. However, even after a transplant, patients most likely will need eyeglasses or contact lenses for clear vision and the rehabilitation can take several months.

Intacs Corneal Implants for the treatment of keratoconus have proven to be a safe, effective and viable option for the treatment of keratoconus. Intacs segments provide a structural element to stabilize the keratoconic cornea, as well as to reduce the patient's myopia and astigmatism. Intacs Corneal Implants significantly improved patients' UCVA's and BCVA's in clinical trials for keratoconus. There was also marked reduction in manifest refraction cylinder and significant changes in the corneal curvature as a result of the Intacs Corneal Implants placement. Quality of vision was significantly improved compared to the preoperative exam as well. Preliminary data are very encouraging and suggest that the Intacs Corneal Implants may defer or eliminate the need for a penetrating keratoplasty procedure.

Physicians who hope to develop a successful practice using Intacs Corneal Implants for the treatment of keratoconus must understand the specific needs of the keratoconic patient and be sure to set the proper expectations for the patient from the outset. Your patients should be provided with a thorough explanation of all of the currently available treatment options. They will want to know the risks and benefits of each procedure and will appreciate a thorough discussion of the risk-to-benefit ratios. In as much as Intacs Corneal Implants are a new treatment option now available for keratoconic patients, it will be extremely important for you to have a thorough understanding of Intacs Corneal Implants for the treatment of keratoconus and alternative treatment options to ensure that patients are truly provided with the basis for an "informed consent."

# PATIENT CONSULTATION, SELECTION & PREOPERATIVE WORK-UP

## 4

The challenge faced by those physicians using Intacs Corneal Implants for the treatment of keratoconus will be to carefully guide patients through the various treatment options (both surgical and non-surgical) currently available, each with their own set of inherent risks and benefits, and to assist them in choosing the best treatment option for their individual needs. Physicians will save time in the long run by discussing the limitations of the proposed procedure and/or therapy prior to surgery.

Specifically, the successful practitioner will enter into a detailed discussion not only about the proposed benefits of the Intacs procedure for the treatment of keratoconus, but also about the potential complications (i.e. induced astigmatism, visual symptoms, lack of refractive effect, etc.). When discussing potential risks with patients, surgeons should be alert to the fact that patients will be increasingly concerned about the inherent risks involved with this new treatment option and how these risks can be minimized. One of the major benefits of Intacs Corneal Implants for the treatment of keratoconus is that the segments can be removed or replaced if the patient is dissatisfied with their outcome. There is also a reduced postoperative recovery period compared to penetrating keratoplasty. It is important to note that, based on the clinical experience to date, patients who have undergone Intacs surgery and who have had a continued progression of their keratoconus or who are dissatisfied with their outcome, can have their Intacs Corneal Implants removed and still be able to go on to have a successful penetrating keratoplasty performed.

In addition to the achievement of improved visual acuity, a more regular corneal surface and a reduction in astigmatism, a distinct advantage of the Intacs Corneal Implants is the excellent safety profile and the fact that the Intacs segments can be removed or replaced, if desired. Clinical studies for the treatment of myopia and keratoconus have demonstrated that Intacs products are safe and effective. The fact that Intacs Corneal Implants can be removed or replaced, if necessary, is especially appealing to cautious patients and physicians. Should removal of the Intacs Corneal Implants be required due to medical circumstances or patient dissatisfaction with their outcome, the Intacs segments can be removed without incident and patients typically return to their preoperative refraction.

As a surgeon who is incorporating Intacs Corneal Implants in your practice, it will be essential for you to keep the lines of communication open between your patient, your staff and yourself. Preoperative discussion of realistic expected visual outcomes and potential postoperative complications should be thoroughly addressed and understood by each patient electing to undergo the Intacs procedure for the treatment of keratoconus.

# PATIENT CONSULTATION, SELECTION & PREOPERATIVE WORK-UP

## 4

### INDICATION FOR USE- KERATOCONUS

As part of the preoperative discussion, patients should be advised that they may not be totally independent of spectacles or contact lenses as a result of this or any other procedure. A realistic goal of the Intacs procedure is to allow patients to be successfully fit/refit with contact lenses in an attempt to restore their functional vision. All patients should be given a copy of the Patient Booklet entitled “Facts You Need to Know About Intacs® Corneal Implants for Treatment of Nearsightedness and Astigmatism Associated with Keratoconus,” provided by Addition Technology.

Intacs Corneal Implants for the treatment of keratoconus are intended for the reduction or elimination of myopia and astigmatism in patients with keratoconus, who are no longer able to achieve adequate vision with their contact lenses or spectacles, so that their functional vision may be restored and the need for a corneal transplant procedure can potentially be deferred.

The specific subset of keratoconus patients proposed to be treated with Intacs Corneal Implants are those patients:

- who have experienced a progressive deterioration in their vision, such that they can no longer achieve adequate functional vision with their contact lenses or spectacles;
- who have clear central corneas;
- who have a corneal thickness of 450 microns or greater at the proposed incision site; and
- who have corneal transplantation as the only remaining option to improve their functional vision.

### INDICATION FOR USE- SEVERE KERATOCONUS

Intacs SK Corneal Implants for the treatment of severe keratoconus are intended for the reduction or elimination of myopia and astigmatism in patients with keratoconus, who are no longer able to achieve adequate vision with their contact lenses or spectacles, so that their functional vision may be restored and the need for a corneal transplant procedure can potentially be deferred.

The specific subset of severe keratoconus patients proposed to be treated with Intacs SK Corneal Implants are those patients:

- who have keratometric readings of 55 D or greater;
- who have experienced a progressive deterioration in their vision, such that they can no longer achieve adequate functional vision with their contact lenses or spectacles;
- who have clear central corneas;
- who have a corneal thickness of 450 microns or greater at the proposed incision site; and
- who have corneal transplantation as the only remaining option to improve their functional vision.

# PATIENT CONSULTATION, SELECTION & PREOPERATIVE WORK-UP

## CONTRAINDICATIONS



Intacs Corneal Implants for keratoconus and Intacs SK Corneal Implants for severe keratoconus are contraindicated:

- in patients with collagen vascular, autoimmune or immunodeficiency diseases;
- in pregnant or nursing women;
- in the presence of ocular conditions, such as recurrent corneal erosion syndrome or corneal dystrophy, that may predispose the patient to future complications; or
- in patients who are taking one or more of the following medications: isotretinoin (Accutane<sup>1</sup>); amiodarone (Coradone<sup>2</sup>); sumatriptan (Imitrex<sup>3</sup>).

## PREOPERATIVE WORKUP

Prior to surgery, the refractive state and the health of the eye needs to be fully evaluated. In some high-volume surgery practices, patients are seen for a screening exam where surgical options are outlined and an optimal surgical procedure for the patient is mutually chosen. A complete examination, including cycloplegic and manifest refractions and visual acuity evaluation must be performed. The crystalline lens must be evaluated to assure that nuclear sclerosis or any other lens opacity is not present. Careful slit lamp biomicroscopy is required to ensure that no corneal irregularities or abnormalities, beyond the diagnosis of keratoconus, are present prior to surgery. Additional preoperative essentials include: direct and indirect ophthalmoscopy through a dilated pupil, evaluation of the optic nerve and measurement of intraocular pressure. Preoperative corneal topography is required for all patients to exclude any patients who would be less than ideal candidates. It is recommended that the baseline evaluation of patients desiring Intacs surgery be performed within 30 days of the procedure. Patients who wear RGP (rigid gas permeable) or PMMA (polymethylmethacrylate) lenses must discontinue their use for at least three weeks.

***It is essential that the refractive information upon which this surgical procedure is based be accurate. An inaccurate refraction could result in an incorrect Intacs Corneal Implants thickness being placed, which may result in a less than optimal result for the patient. It is the sole responsibility of the surgeon to ensure that accurate information for each patient is obtained.***

<sup>1</sup> Accutane<sup>®</sup> is a registered trademark of Hoffman-LaRoche Inc.

<sup>2</sup> Cordarone<sup>®</sup> is a registered trademark of Sanofi.

<sup>3</sup> Imitrex<sup>®</sup> is a registered trademark of Glaxo Group Ltd.

# PATIENT CONSULTATION, SELECTION & PREOPERATIVE WORK-UP

## 4 GENERAL WARNINGS:

**RESTRICTED DEVICE:** U.S. Law restricts this device to sale, distribution and use by or on the order of a physician.

Specific training is required before a physician is qualified to perform the Intacs Corneal Implants procedures for treatment of keratoconus or severe keratoconus. Physicians must successfully complete an Addition Technology-approved training program, read and understand the Intacs® Corneal Implants for Keratoconus Instructions For Use and the Intacs® Surgeon Training Manual for the Treatment of Keratoconus prior to performing the procedure.

Performance of the Intacs Corneal Implants procedure, other than as specified in the Instructions For Use and the Intacs® Surgeon Training Manual for the Treatment of Keratoconus, may result in an undesirable outcome.

All patients must be given the opportunity to read and understand the Patient Information Booklet, entitled “Facts You Need to Know About Intacs® Corneal Implants for Treatment of Nearsightedness and Astigmatism Associated with Keratoconus,” and to have you answer all their questions to their satisfaction before giving consent for the procedure.

### **WARNINGS:**

Some patients with large dilated pupil diameters ( $\geq 7.0$  mm) are predisposed to low light visual symptoms postoperatively and should be appropriately advised.

The long-term effect of Intacs Corneal Implants on endothelial cell density has not been established. Additional long-term data are being collected in the U.S. myopia clinical trials.

Under mesopic conditions, patients may experience some loss in contrast sensitivity at low spatial frequencies (1.5 cycles per degree).

# PATIENT CONSULTATION, SELECTION & PREOPERATIVE WORK-UP

## 4 PRECAUTIONS:

Use of the Vacuum Centering Guide subjects the eye to increased intraocular pressure. **Continuous application of vacuum should be limited to 3 minutes or less and to no more than 750 mBar.** If it is necessary to reapply the Vacuum Centering Guide, wait 5 minutes to allow normal vascular perfusion of the eye to occur before reestablishing suction.

Intacs Corneal Implants are not recommended in patients with systemic diseases likely to affect wound healing, such as insulin-dependent diabetes or severe atopic disease.

Intacs Corneal Implants are not recommended in patients with a history of ophthalmic *Herpes simplex* or *Herpes zoster*.

A temporary decrease in central corneal sensation has been noted in some patients. No clinical consequences were demonstrated in the U.S. clinical trials.

The safety and effectiveness of alternative refractive procedures following the removal of Intacs Corneal Implants have not been established.

**Intacs Corneal Implants are intended for single use only; do not reuse or resterilize.**

The safety and effectiveness of Intacs Corneal Implants have **NOT** been established:

- in patients with progressive myopia or astigmatism, nuclear sclerosis or other crystalline lens opacity, corneal abnormality, or previous corneal surgery or trauma;
- for patients under 21 years of age;
- for corneas that are less than 450 microns thick at the proposed incision site; or
- in long-term use.

# 5 Preoperative Preparation: Instruments & Supplies, Patient Preparation, Medication and Infection Prevention

# PREOPERATIVE PREPERATION - *INSTRUMENTS & SUPPLIES*



SURGICAL  
INSTRUMENTS  
DESIGNED FOR  
INTACS PROCEDURE

Custom surgical instruments, designed and manufactured for Addition Technology, are required to perform the surgical procedure for placement of Intacs Corneal Implants.

- Inspection Gauge
- Procedure Marker
- Pocketing Hook
- KV 2000 Vacuum System
- Vacuum Centering Guide (VCG) - Sloped Shelf
- Symmetric Glide with Handle
- Clockwise (CW) and Counterclockwise (CCW) Corneal Separators
- Intacs® Forceps

The instruments and their use are described in detail in Chapter 6, Intacs Corneal Implants Surgical Technique for the Treatment of Keratoconus and Severe Keratoconus.

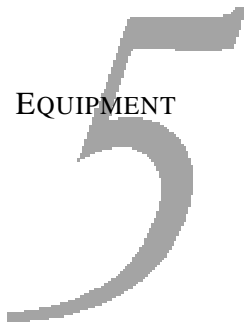
ADDITIONAL  
INSTUMENTS,  
EQUIPMENT AND  
SUPPLIES

The following commercially-available surgical instruments, equipment and supplies are not designed or manufactured by Addition Technology. Unless noted, they are required to perform the surgical procedure.

## **Instruments**

- 11 mm Zone Marker
- Calibrated Diamond Knife with 15° angled blade  
( A 45° angled blade is NOT recommended.)
- Sinsky Hooks
- Conjunctival Forceps
- Needle Holding Forceps
- Tying Forceps
- Scissors
- Lid speculum

# PREOPERATIVE PREPERATION - *INSTRUMENTS & SUPPLIES*



## EQUIPMENT

Surgical microscope  
Microscope (or other means of calibrating diamond knife setting)  
Ultrasound Pachymeter  
Calculator (necessary if pachymeter does not provide incision depth calculations)  
Sharps Container

## STERILE SUPPLIES

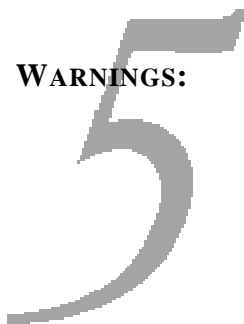Vacuum tubing  
Murocel<sup>®</sup> Sponge (anesthetic sponge for use with topical anesthesia)  
Surgical Spears/Microsponges (lint-free)  
Sterile balanced salt solution  
Eye drape  
Eye shield  
10-0 nylon or 11-0 nylon ophthalmic suture (11-0 Recommended)  
Latex gloves (talc-free)  
Sterile surgical marking pen  
Povidone-Iodine 2.5% and 5% solution  
1% Carboxymethylcellulose Sodium ocular lubricant (optional)  
Sterile water

Be sure to order all necessary surgical instruments, equipment and supplies well in advance of the scheduled surgeries.

NOTE: *These lists are not intended to be exhaustive.*

# PREOPERATIVE PREPERATION - INSTRUMENTS & SUPPLIES

## WARNINGS:



## EXAMINE FOR DEFECTS

## STEAM STERILIZATION INSTRUCTIONS

## STORAGE

### CARE AND HANDLING OF INTACS SURGICAL INSTRUMENTS

All instruments are supplied nonsterile and must be cleaned and sterilized prior to initial use.\*

Inspect all surgical instruments for damage or defects prior to each use.

Never use saline solution for cleaning surgical instruments.

CW/CCW Corneal Separators should always be sterilized and stored in the protective cases provided.

\* Please refer to the respective Instrument Instructions for Use for complete information.

*Examine each individual instrument for defects or damage prior to each use. Do not use damaged or defective instruments. If any instrument is found to be defective or damaged upon initial receipt, or after use, please contact your Addition Technology representative and/or Addition Technology Customer Service immediately.*

Addition Technology recommends that the user determine an effective steam sterilization cycle for sterilization of the surgical instruments. The following steam sterilization cycles have been evaluated. The recommended cycle temperatures, dwell times and sterilization configurations are provided below.

#### RECOMMENDED STEAM STERILIZATION CYCLES FOR UNWRAPPED INSTRUMENT CONFIGURATION

	Gravity Air Displacement	Steam Flush Pressure Pulse	Prevacuum Conditioning
Temperature	132° C	132° C	132° C
Dwell Time	7 minutes	4 minutes	4 minutes

#### RECOMMENDED STEAM STERILIZATION CYCLES FOR DOUBLE-WRAPPED\*\* INSTRUMENT CONFIGURATION

	Gravity Air Displacement	Steam Flush Pressure Pulse	Prevacuum Conditioning
Temperature	121°C	121°C	132°C
Dwell Time	60 minutes	50 minutes	4 minutes

\*\* Instruments double wrapped using a single-use, non-woven, lint-free fabric for sterile goods wrapping.

Surgical instruments are to be stored in a standard instrument tray according to standard procedures in a dry, dust-free area.

# PREOPERATIVE PREPERATION - *PATIENT PREPARATION*

## 5

### PATIENT PREPARATION

AS WITH ANY SURGICAL PROCEDURE, CARE MUST BE TAKEN TO MINIMIZE THE RISK OF INFECTION TO THE PATIENT. INFECTION PREVENTION GUIDELINES HAVE BEEN DEVELOPED WITH INPUT FROM THE U.S. MYOPIA PHASE III CLINICAL INVESTIGATORS, AN INFECTION CONTROL EXPERT AND THE DATA AND SAFETY MONITORING BOARD. STEPS CRITICAL FOR INFECTION PREVENTION AND MANAGEMENT DURING THE INTACS SURGICAL PROCEDURE FOR PLACING INTACS CORNEAL IMPLANTS ARE NOTED WITH THE FOLLOWING SYMBOL (⊙) AND SHOULD BE FOLLOWED CAREFULLY.

#### *24 to 48 hours before surgery*

- ✓ If patients wear eye makeup, they should be instructed to discontinue mascara application to the eyelashes and other eye makeup applied to the lid and lid margins for 2 – 3 days before the procedure.
- ✓ Have patient apply one drop of Polytrim<sup>®1</sup> ophthalmic solution (or equivalent) in operative eye at bedtime on the night prior to the procedure. Apply one drop in operative eye every hour beginning three hours prior to the procedure (total of three applications).
- ✓ The patient has received the Patient Information Booklet on Intacs for keratoconus and the informed consent process has been discussed.
- ✓ The patient should follow all preoperative instructions given by the surgeon.

### OTHER PREPARATION

- ✓ Each instrument should be inspected for damage or defects. If there are any problems, notify Addition Technology immediately.
- ✓ Complete all necessary administrative paperwork.
- ✓ Prior to the beginning of the surgical procedure, any required medication should be ordered by the surgeon and/or the anesthesiologist. Reference the following table, *Recommended Medication and Treatment Regimen for Intacs Corneal Implants Surgical Procedure*.

<sup>1</sup> Polytrim<sup>®</sup> is a registered trademark of Allergan, Inc.

# PREOPERATIVE PREPARATION - MEDICATION

# 5

## RECOMMENDED MEDICATION AND TREATMENT REGIMEN FOR INTACS CORNEAL IMPLANTS SURGICAL PROCEDURE

	Operative, Postoperative Medications	Eye Protection	Analgesic Medication
Preoperative	Topical anesthesia, local anesthesia or topical anesthesia with IV or oral conscious sedation, as deemed appropriate by the surgeon.	–	–
Intraoperative	If required, the following types of anesthesia may be administered intraoperatively: topical, local, topical with oral conscious sedation.	–	–
Postoperative	Post-suturing and while still in the surgical suite: antibiotic-steroid combination, for example, tobramycin/dexamethasone 0.3% (3 mg)/0.1% (1 mg) or equivalent ointment, ½ in. or solution, 1 drop.	Eye shield overnight.	Analgesics: acetaminophen, meperidine/promethazine 50 mg/25 mg, codeine phosphate/acetaminophen -30 mg/300 mg (or equivalent)
Discharge	Antibiotic-steroid combination solution tobramycin/dexamethasone 0.3% (3 mg)/0.1% (1 mg) (or equivalent) 1-2 drops q.i.d x 1 week or until achieve complete reepithelialization; full strength topical corticosteroid; prednisolone acetate 1% (or equivalent) 1 drop q.i.d. x 3 days then taper usage. <sup>1</sup>	Eye shield at night to prevent eye rubbing during healing process for a minimum of 3 weeks.	–

<sup>1</sup> It is recommended that all routine postoperative ophthalmic medications be discontinued by the end of the second postoperative week.

Oral conscious sedation with topical or local anesthesia is recommended for this procedure, based on the individual preferences of the surgeon and the patient. The surgeon and/or anesthesiologist will select the anesthetic agents and techniques to be used for each patient. The surgeon may elect to have the patient monitored during anesthesia by an anesthesiologist or an anesthesiologist.

### DAY OF SURGERY

- © During the preoperative exam, careful evaluation of the lid margin and meibomian glands should be made to rule out blepharitis and/or meibomitis. If present, these conditions should be treated with a course of topical and/or systemic antibiotics prior to the procedure. In some cases, cultures of the lid margin and meibomian gland secretions may be indicated and repeated until the infectious process is brought under control by specific antibiotic therapy. ***The procedure should not be performed if blepharitis and/or meibomitis are present.***

# PREOPERATIVE PREPARATION - MEDICATION

## 5 PRECAUTION:

Using sterile technique, saturate a microsponge pledget, anesthesia ring or equivalent in topical anesthesia and place on the sclera outside the cornea. Avoid overhydrating the cornea at this point to prevent the formation of a “lacrimal lake.”

**Chemosis may result if local anesthesia is used. If significant chemosis occurs, it is recommended that the surgical procedure be rescheduled.**

Betadine<sup>®1</sup> scrubs and/or paint should be used for sterile preparation of the operative field. In the event of patient allergy to Betadine, an alternate surgical scrub solution may be used. Care must be taken to avoid manipulating or irritating the patient’s conjunctiva during the preoperative preparations.

- ⊙ Five to ten minutes prior to the procedure, paint eyelid margins with 5% Betadine. Dilution of the Betadine is not recommended. Allow to air dry and to remain on lid margins throughout the procedure. Antimicrobial efficacy for Betadine is a function of contact time.
- ⊙ Apply iodine solution [povidone-iodine 5% solution, dilute with sterile balanced salt solution (BSS) 1:1 for a 2.5% solution] to the cul-de-sac. Irrigate the conjunctival sac before draping patient’s eye.

### NOTE:

*To minimize dehydration of the corneal epithelium, irrigate the cornea frequently and avoid using excessive illumination during the operative procedure.*

The Intacs surgical procedure should be performed in a lint-free environment to reduce the risk of introducing fibers into the intrastromal tunnel. **No gauze or other material with cotton fibers should be used in the sterile field. It is also recommended that the surgeon and scrub nurse wear talc-free gloves.**

Standard ophthalmic draping procedure should be followed. The use of a fenestrated plastic eye drape is recommended. Attempt to isolate the eyelashes from the surgical field (see section entitled “Recommendation for Eyelid Isolation”).

### PRECAUTION:

**It is recommended that the surgeon completely isolate the eyelashes and lid margins during the surgical procedure to prevent infection.**

- ⊙ The surgeon should pay particular attention to the complete isolation of the eyelashes and lid margins during the procedure. **This may be accomplished with a Steri-strip<sup>®2</sup> or with a plastic drape with an adhesive.** The lashes and margins must be completely isolated from the surgical field. **The surgeon should be careful to avoid touching any of the surgical instruments or the Intacs Corneal Implants to the eyelashes, meibomian gland secretions or the lacrimal lake that accumulates during the procedure to prevent a postoperative infection.**

<sup>1</sup> Betadine<sup>®</sup> is a registered trademark of The Purdue, Frederick Company.

<sup>2</sup> Steri-strip<sup>®</sup> is a registered trademark of 3M Corporation.

# PREOPERATIVE PREPARATION - *MEDICATION*

## 5

A wire lid speculum (Kratz Barraquer or equivalent design) should be used to minimize the manipulation of the eyelids during the placement of the Vacuum Centering Guide (VCG) by widely separating the eyelids. The wire lid speculum allows for easy application of the VCG and assists in keeping the lid margins away from the sterile field. It is important not to allow the surgical instruments or Intacs Corneal Implants to touch the lid margins during the procedure to prevent a postoperative infection. **A recommended procedure for isolation of the lids is provided at the end of this section.**

**PRECAUTION:**

**Avoid overtightening the lid speculum to reduce the incidence of postoperative ptosis.**

BSS or an antibiotic ophthalmic solution is recommended, in the event that lubrication of the Intacs Corneal Implants or the surgical site is desired.

# PREOPERATIVE PREPARATION- *INFECTION PREVENTION*

## 5 RECOMMENDATION FOR EYELID ISOLATION

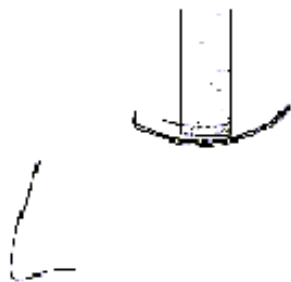
The following recommendations have been provided as intraoperative preparation techniques for the isolation of the eyelashes from the sterile surgical field. The technique requires the use of 1/2-inch Steri-strips and a 3M<sup>®1</sup> plastic incise drape (3M #1060 or equivalent). The Steri-strips are cut in half across their long axis.

Prepare patient's skin and eyelids with Betadine scrubs as per routine. Tell the patient that you are going to assist them in keeping their eyes open for the procedure. This will relax them for placement of the Steri-strips. Ask the patient to gently close their eyes. Apply the Steri-strip to the skin overlying the superior tarsal plate at the midpoint of the upper lid (Figure 1). Instruct the patient to look up. With the lids fully elevated, secure the Steri-strip to the head drape (Figure 2). With the superior eyelid now fixed in the fully elevated position, the superior eyelashes may appear slightly everted.

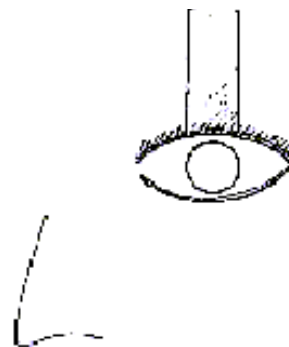
Place a second Steri-strip tangentially along the eyelid on one side of the midline so that the eyelashes are covered (Figure 3). Similarly, place an additional Steri-strip on the other side of the midline (Figure 4). Apply the end of a fourth Steri-strip to the midpoint of the inferior eyelid. Retract the inferior eyelid and fix the Steri-strip to the skin along the malar eminence (Figure 5). Position the plastic drape in the usual fashion so that the incision of the drape is horizontal across the middle of the interpalpebral fissure and the relaxing incisions are above and below at the midline of the drape. Place the speculum so that the plastic leaves of the incise drape are reflected around the opened eyelids. With the Steri-strips and plastic drape positioned in this manner, the eyelashes should be securely isolated from the surgical field.

<sup>1</sup> 3M<sup>®</sup> is a registered trademark of 3M Corporation.

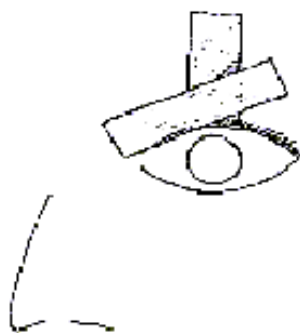
# PREOPERATIVE PREPARATION- *INFECTION PREVENTION*



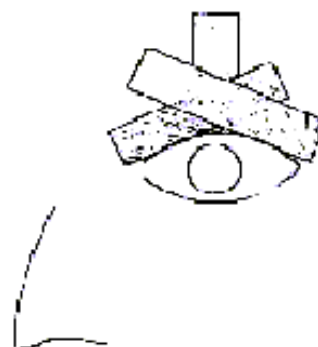
**Figure 1**



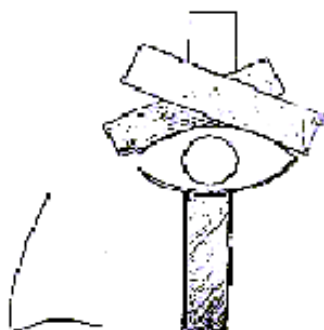
**Figure 2**



**Figure 3**



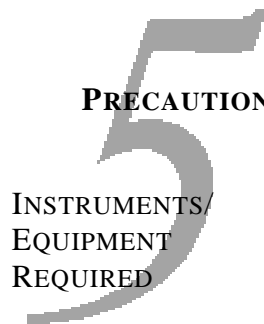**Figure 4**



**Figure 5**

# PREOPERATIVE PREPARATION-

## *CORNEAL SEPARATOR INSPECTION*



**PRECAUTION:**

**Before the start of Intacs Corneal Implants surgery, inspect the Corneal Separators for concentricity and planarity using the Inspection Gauge.**

- CW Corneal Separator
- CCW Corneal Separator
- Inspection Gauge
- Microscope

Use the notched end of the Inspection Gauge to inspect the Corneal Separators for concentricity by sliding the Corneal Separator blade into the notch.

**PRECAUTION:**

**Each Corneal Separator should rotate freely. If it does not, the Corneal Separator is warped and should not be used.**

Use the flat end of the Inspection Gauge to inspect the Corneal Separators for planarity by sliding the gauge into the Corneal Separator and comparing the space between the flat end of the gauge and the Corneal Separator.

**PRECAUTION:**

**The end of the Inspection Gauge should be parallel to the blade of the Corneal Separator all the way around. If it is not, the Corneal Separator is bent and should not be used.**

Inspect the edge of the Corneal Separator blade for nicks, artifacts and cellular debris.

**PRECAUTION:**

**Do not use a Corneal Separator if it is not clean or if it is damaged in any way.**

# PREOPERATIVE PREPARATION-

## *DETERMINATION OF DIAMOND KNIFE SETTING*

# 5

INSTRUMENTS/  
EQUIPMENT  
REQUIRED

Preoperatively, verify calibration of the diamond knife and determine the proper knife setting to position the Intacs Corneal Implants at 68% depth in the cornea.

NOTE: *Micronscope calibration/verification of the diamond knife is preferable.*

- Topical anesthesia drops
- Ultrasonic pachymeter

Instill anesthesia drops. Disinfect the tip and handle of the pachymeter probe with an alcohol swab. Take several readings of the corneal thickness at the incision site for each operative eye to establish the average corneal thickness.

**SET DIAMOND KNIFE TO 68% DEPTH OF THE PACHYMETRY READING AT THE INCISION SITE**

NOTE: *The minimum corneal thickness measurement at the incision site must be 450 microns.*

# PREOPERATIVE PREPERATION - *SETTING DIAMOND KNIFE*

5  
INSTRUMENTS/  
EQUIPMENT  
REQUIRED

Extend the blade of the knife to a distance beyond the footplate that corresponds to the pre-calculated value.

- D&K Guarded 15° diamond knife
- Micronscope

Under the micronscope, set the diamond knife to the pre-calculated value. If necessary, add any factor determined during the calibration of the knife for accurate setting of the diamond.

**PRECAUTION:**

**Once the knife is set, DO NOT HANDLE the knife by the micrometer end, as this will change the setting.**

# 6 Intacs Corneal Implants Surgical Technique

# INTACS CORNEAL IMPLANTS SURGICAL TECHNIQUE



## INTRODUCTION

This section contains detailed step-by-step instructions for performing the Intacs surgical procedures for the treatment of keratoconus and severe keratoconus.

The Intacs Corneal Implants Surgical Procedure Flow Chart shown on page 6-2, presents a step-by-step outline of the surgical procedure utilizing the 10-Step Prolate System for keratoconus. This flow chart is followed by detailed instructions, that have been organized using the same flow, explaining the key points and warnings/precautions relevant for each step of the surgical procedure.

The Intacs SK Corneal Implants-Severe Keratoconus Surgical Procedure Flow Chart shown on page 6-4, presents a step-by-step outline of the surgical procedure utilizing the 10-Step Prolate System for severe keratoconus. This flow chart is followed by detailed instructions, that have been organized using the same flow, explaining the key points and warnings/precautions relevant for each step of the surgical procedure.

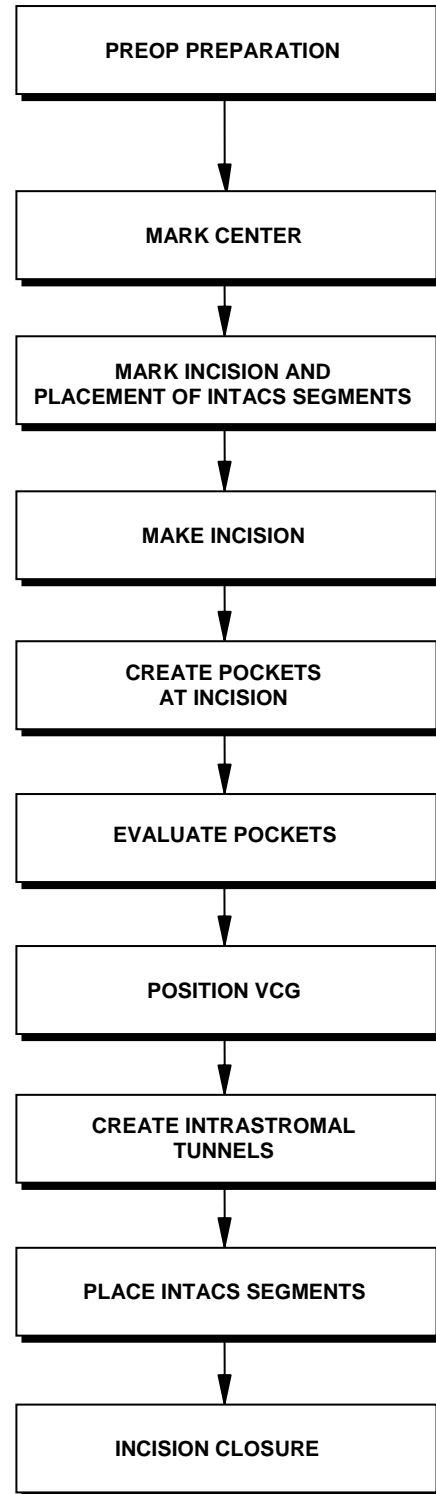
As you are becoming familiar with the respective Intacs surgical procedures, we recommend that you make a practice of referring to the specific surgical procedure flow chart frequently. This will help you better understand and remember the sequence of steps involved in the respective procedure. The flow chart can also serve as a handy reference for required instruments and materials, key points, and warnings and precautions associated with each step of the procedure.

# INTACS CORNEAL IMPLANTS-KERATOCONUS SURGICAL PROCEDURE FLOW CHART (10-STEP PROLATE SYSTEM)

## **Instruments/Materials**

---

- Anesthesia Ring (for use with topical anesthesia)
- Inspection Gauge
- Povidone-Iodine 2.5% and 5% Solution
- Lid Speculum
  
- Sterile Marking Pen
- 11 mm Zone Marker
- Sinskey Hook
  
- Sterile Marking Pen
- Procedure Marker
  
- Calibrated Diamond Knife with 15° angled blade (or rectangular blade of 1 mm or less)
  
- Pocketing Hook
  
- Symmetric Glide
  
- Anesthesia Ring (Remove prior to VCG application)
- Topical Anesthetic
- Vacuum Centering Guide (VCG)
- Procedure Marker
- Vacuum Centering Guide
- Symmetric Glide
- Corneal Separators (CW/CCW)
  
- Intacs Forceps
- Sinskey Hook
- Intacs Carrier
  
- Ophthalmic Suture (11-0 or 10-0; 11-0 recommended)



# INTACS CORNEAL IMPLANTS-KERATOCONUS SURGICAL PROCEDURE FLOW CHART (10-STEP PROLATE SYSTEM)

## Key Points

- Iodine preparation of eye
- Avoid excessive manipulation or irritation of the conjunctiva
- Use lint-free drapes & talc-free gloves
- Mark the geometric center of the cornea
- Reference off the geometric center mark
- Incision mark is placed at 9:00 (OD) and 3:00 (OS)
- Verify that the placement marks are at least 1 mm from the limbus
  
- Cut entire length of incision mark
- Remove loose epithelium from incision area
- Irrigate incision area
  
- From the base of the incision, create a corneal pocket on each side of the incision using the Pocketing Hook
- Pockets should be at the same depth across the full width of incision, within the same stromal plane and slightly longer than the Symmetric Glide
  
- Estimate pocket depth
- Create deeper pockets, if necessary
  
- Locate VCG & Procedure Marker on center mark
- Apply vacuum at 400-500 mBar
- Confirm proper placement
- Increase vacuum to 600-667 mBar
  
- Insert Symmetric Glide into the first pocket
- Rotate Corneal Separator blade tip under Symmetric Glide
- Rotate Corneal Separator to create tunnel
- Create intrastromal tunnel on the second side
- Release vacuum, remove VCG
  
- Irrigate incision area
- Insert one Intacs segment into each intrastromal tunnel
- One Intacs segment is placed inferiorly and the other is placed superiorly
- Align the outer edge of each segment under the appropriate placement mark
  
- Approximate incision edges to ensure proper healing
- Place one or two interrupted sutures, evenly spaced. Suture depth should be to the level of the stromal pocket
- Suture knots should be buried

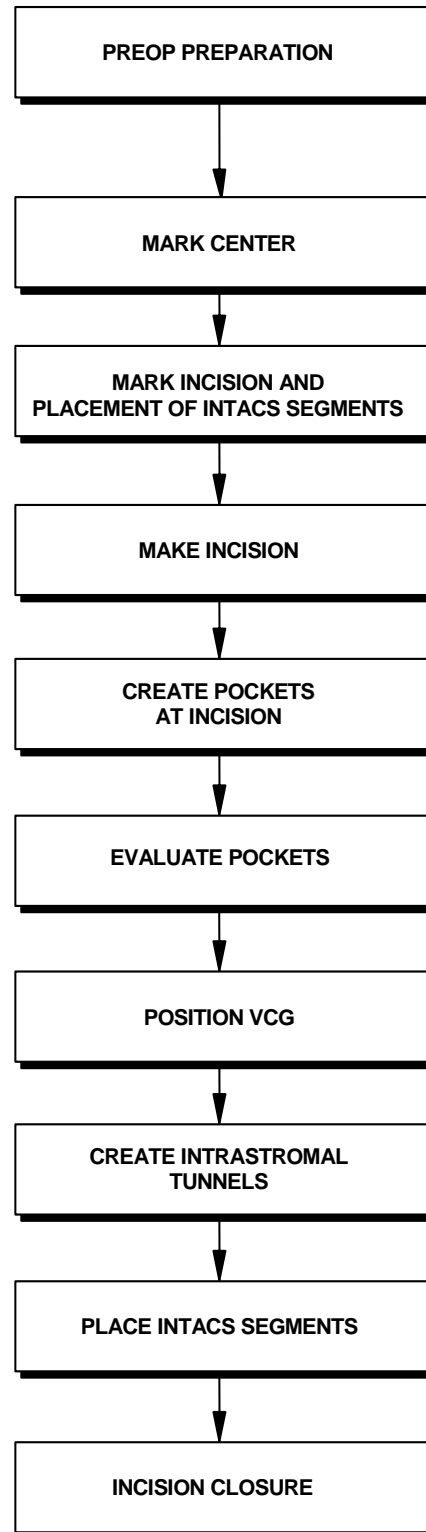
## Warnings/Precautions

- Completely isolate eyelashes
- Avoid overtightening the lid speculum
- Frequently irrigate the cornea with balanced saline solution during the operative procedure
- Chemosis may result if local anesthesia used
- Avoid contacting the Intacs segments & instruments with the lids, lid margins, lashes & lacrimal fluid
- Visually inspect instruments prior to use
- Inspect Corneal Separators with Inspection Gauge
- Pilocarpine to constrict pupil is not recommended
  
- Set diamond knife to 68% of pachometry reading at the incision site
- Verify diamond knife setting
- Stay 1 mm away from the limbus
  
- Create pockets at the full depth of the incision to avoid shallow implant depth
  
- Position vacuum port temporally
- Limit continuous VCG time to 3 minutes or less and applied vacuum to 750 mBar
  
- Stop creating the tunnel if excessive resistance or “tissue wave” is encountered, consider creating a deeper pocket and tunnel
- Stop the procedure in the event of a posterior chamber perforation or anterior corneal surface perforation
  
- Visually inspect Intacs segments prior to insertion
- Avoid contact of Intacs segments with iodine and/or epithelial surface
  
- Avoid epithelial ingrowth into stroma
- Tension across the sutures should be evenly applied
- Avoid overtightening sutures
- Incision edges must be apposed at end of procedure

# INTACS SK CORNEAL IMPLANTS-SEVERE KERATOCONUS SURGICAL PROCEDURE FLOW CHART (10-STEP PROLATE SYSTEM)

## Instruments/Materials

- Anesthesia Ring (for use with topical anesthesia)
- SK Inspection Gauge
- Povidone-Iodine 2.5% and 5% Solution
- Lid Speculum
  
- Sterile Marking Pen
- 11 mm Zone Marker
- Sinskey Hook
  
- Sterile Marking Pen
- SK Procedure Marker
  
- Calibrated Diamond Knife with 15° angled blade (or rectangular blade of 1 mm or less)
  
- Pocketing Hook
  
- Symmetric Glide
  
- Anesthesia Ring (Remove prior to VCG application)
- Topical Anesthetic
- Vacuum Centering Guide (VCG)
- SK Procedure Marker
  
- Vacuum Centering Guide
- Symmetric Glide
- SK Corneal Separators (CW/CCW)
  
- Intacs Forceps
- Sinskey Hook
- Intacs Carrier
  
- Ophthalmic Suture  
(11-0 or 10-0; 11-0 recommended)



# INTACS SK CORNEAL IMPLANTS-SEVERE KERATOCONUS SURGICAL PROCEDURE FLOW CHART (10-STEP PROLATE SYSTEM)

## Key Points

- Iodine preparation of eye
- Avoid excessive manipulation or irritation of the conjunctiva
- Use lint-free drapes & talc-free gloves
- Mark the geometric center of the cornea
- Reference off the geometric center mark
- Incision mark is placed at the axis of positive cylinder on the temporal side
- Verify that the placement marks are at least 2 mm from the limbus
  
- Irrigate incision area
- Cut entire length of incision mark
- Remove loose epithelium from incision area
- Keep entire cornea hydrated for the remainder of the procedure
  
- From the base of the incision, create a corneal pocket on each side of the incision using the Pocketing Hook
- Pockets should be at the same depth across the full width of incision, within the same stromal plane and slightly longer than the Symmetric Glide
  
- Estimate pocket depth
- Create deeper pockets, if necessary
  
- Locate VCG & SK Procedure Marker on center mark
- Apply vacuum at 400-500 mBar
- Confirm proper placement
- Increase vacuum to 600-667 mBar
  
- Insert Symmetric Glide into the first pocket
- Rotate SK Corneal Separator blade tip under Symmetric Glide
- Rotate SK Corneal Separator to create tunnel
- Create intrastromal tunnel on the second side
- Release vacuum, remove VCG
  
- Irrigate incision area
- Insert one Intacs segment into each intrastromal tunnel
- One Intacs segment is placed inferiorly and the other is placed superiorly
- Align the outer edge of each segment under the appropriate placement mark
  
- Approximate incision edges to ensure proper healing
- Place one or two interrupted sutures, evenly spaced. Suture depth should be to the level of the stromal pocket
- Suture knots should be buried

## Warnings/Precautions

- Completely isolate eyelashes
- Avoid overtightening the lid speculum
- Frequently irrigate the cornea with balanced saline solution during the operative procedure
- Chemosis may result if local anesthesia used
- Avoid contacting the Intacs segments & instruments with the lids, lid margins, lashes & lacrimal fluid
- Visually inspect instruments prior to use
- Inspect Corneal Separators with Inspection Gauge
- Pilocarpine to constrict pupil is not recommended
  
- Set diamond knife to 68% of pachometry reading at the incision site
- Verify diamond knife setting
- Stay 2 mm away from the limbus
  
- Create pockets at the full depth of the incision to avoid shallow implant depth
  
- Position vacuum port temporarily
- Limit continuous VCG time to 3 minutes or less and applied vacuum to 750 mBar
  
- Stop creating the tunnel if excessive resistance or “tissue wave” is encountered, consider creating a deeper pocket and tunnel
- Stop the procedure in the event of a posterior chamber perforation or anterior corneal surface perforation
  
- Visually inspect Intacs segments prior to insertion
- Avoid contact of Intacs segments with iodine and/or epithelial surface
  
- Avoid epithelial ingrowth into stroma
- Tension across the sutures should be evenly applied
- Avoid overtightening sutures
- Incision edges must be apposed at end of procedure


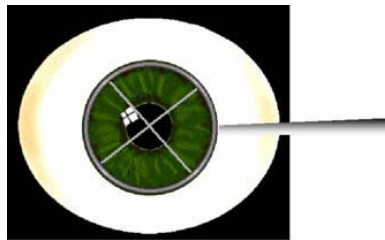
# MARK CENTER

## PRECAUTION:

To minimize the risk of infection, the surgeon should avoid contacting the Intacs Corneal Implants and surgical instruments with the lid margins, the epithelial surface, the eyelashes, meibomian gland secretions or lacrimal fluid that can accumulate during the procedure.

INSTRUMENTS/  
EQUIPMENT  
REQUIRED

- Sterile Marking Pen
- 11 mm Zone Marker
- Sinskey Hook



Mark the geometric center of the cornea with a blunt instrument using an operating microscope for fixation. An 11 mm zone marker can be used to aid in locating the center point. The 11 mm zone marker is placed on the limbus and pressed down so that the cross hairs make a mild indentation mark at the geometric center of the cornea. Care should be taken to ensure that the cross hairs are not bent. A blunt Sinskey Hook or other corneal marker is then used to mark the geometric center of the cornea, using the sterile marking pen to ink the tip of the blunt Sinskey Hook. Adequate marking with ink should be made since this same mark is used later in the procedure for centration of the Vacuum Centering Guide. The marked geometric center of the cornea should coincide with the entrance pupil and should be slightly inferior and temporal to the center of the entrance pupil in the undilated state. Use this center mark as the reference point throughout the surgical procedure.

**NOTE:** *For treatment of severe keratoconus, the surgeon may elect to center on the patient's pupil instead of the geometric center of the cornea since the Intacs SK segments will be placed closer to the center of the optical zone.*

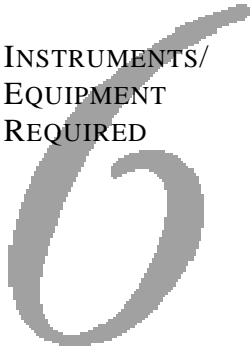
**PRECAUTION:** **Use of pilocarpine to constrict the patient's pupil is not recommended because it may cause chemosis, which could lead to subsequent fixation problems with the Vacuum Centering Guide (VCG).**

Prior to use in the procedure, all surgical instruments in the sterile field are to be rinsed with sterile water and wiped using a lint-free instrument wipe.

**NOTE:** *Avoid excessive illumination of the operative eye with the operating microscope light as this will dehydrate the cornea. Frequently irrigate the cornea with balanced saline solution during the surgical procedure to keep the eye hydrated.*

# MARK INCISION AND PLACEMENT OF INTACS SEGMENTS

INSTRUMENTS/  
EQUIPMENT  
REQUIRED



- Sterile Marking Pen
- Procedure Marker

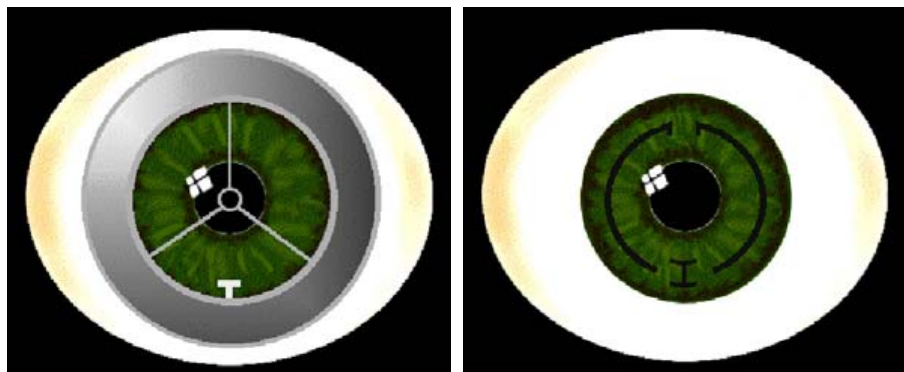


With a sterile marking pen, apply a light coating of ink on the contact surface of the Procedure Marker.

Using the Procedure Marker, with the incision mark positioned at 3:00, 9:00 or 12:00 (depending on horizontal vs. vertical Intacs placement), reference the marked center and align center of reticule. Slowly lower the Procedure Marker until it contacts the surface evenly to transfer the ink. Lift the Procedure Marker straight up after contact is made. This will mark the radial incision placement and indicate the final positioning of the Intacs Corneal Implants. Do not “rock” the Procedure Marker as this may smear the markings.

Remove any excess ink from the Procedure Marker by thoroughly wiping the contact surface of the instrument using a lint-free instrument wipe.

Visually verify that the Intacs Corneal Implants placement marks are at least 1 mm from the limbus in all directions to ensure that the tunnels will not encroach upon the limbus. If the placement marks are too close to the limbus, remark the cornea closer to the center. Use this new center mark as the reference point throughout the surgical procedure.



# MAKE INCISION

INSTRUMENTS/  
EQUIPMENT  
REQUIRED

## PRECAUTIONS:

- Calibrated  
Diamond Knife  
with 15° angled blade  
(or rectangular blade 1 mm or less)



**Verify that the diamond knife is set to 68% of the pachometry reading at the incision site. An incorrect knife setting can cause an anterior chamber perforation or corneal surface perforation. (The minimum corneal thickness at the incision site must be 450 microns.)**

The diamond should have an angled cutting edge of 15°, or less, or have a rectangular blade of 1 mm width or less.

## NOTE:

*A 45° angled blade is not recommended to be used for this procedure.*

- Increase magnification on operating microscope (optional).
- Hydrate the cornea prior to making the incision to prevent epithelial sloughing from dragging footplates.
- Verify proper knife setting and blade extension under the operating microscope.
- Plunge the knife into the cornea at the central edge of the incision mark and seat the footplate firmly onto the cornea creating a “dimple” on the surface of the cornea from the footplate pressure.
- Maintaining firm contact on the cornea, cut to the outer (peripheral) edge of the incision mark, then retrace the cut back to the central edge.
- Lift the knife straight out of the cornea.
- Irrigate the cornea to remove any loose epithelium.

## PRECAUTION:

**To avoid neovascularization into the incision region, special care should be taken to ensure that the incision is kept approximately 1-2 mm away from the limbus.**

Thoroughly irrigate the incision area after completing the incision and prior to inserting any instrument or Intacs segment into the intrastromal tunnel.

## NOTE:


*Use a lint-free surgical microsponge to remove any loose epithelial cells and excess balanced saline solution from the edges of the incision. The epithelium may be rolled away from the incision edges.*



# CREATE POCKETS AT INCISION/EVALUATE POCKETS

INSTRUMENTS/  
EQUIPMENT  
REQUIRED

NOTE:



## CREATE AND EVALUATE THE POCKETS

- Pocketing Hook
- Symmetric Glide

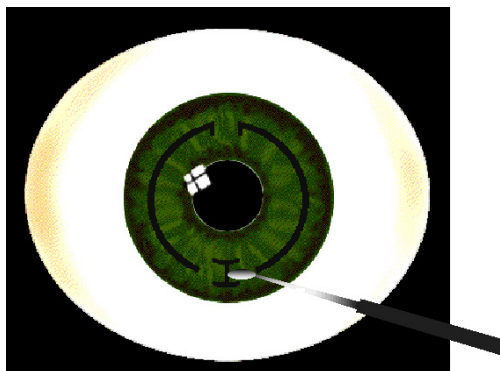


*It is recommended that the surgeon increases magnification at this point to enhance visualization during this step.*

PRECAUTION:

**To avoid shallow intrastromal tunnels, create the pockets at the full depth of the incision and evaluate pocket depth. The pockets should be treated carefully, rotating the footplate of the Pocketing Hook within a single intrastromal plane.**

Using a “heel to toe” motion insert the base, or “foot”, of the Pocketing Hook to the base of the incision. The base of the hook should rest flat on the base of the incision. **DO NOT** contact the base of the incision with the tip of the hook, rather lean the handle forward slightly applying posterior pressure to the tip of the Pocketing Hook. This initiates delamination of the stromal layers at the base of the incision. Under direct visualization, initiate the clockwise pocket by rotating the hook to the left and moving the hook back and forth on a singular plane across the entire length of the incision. Remove the Pocketing Hook, and repeat the same steps on the right side for the counterclockwise pocket. **DO NOT** rotate the Pocketing Hook from the left side to the right side across the base of the incision. Test fit the Symmetric Glide in the completed pockets. Pockets should be at the same depth across the full width of the incision, within the same stromal plane and slightly longer than the width of the Symmetric Glide.



NOTE:

*The Clockwise and Counterclockwise Glide Blades may be used as alternative instruments to the Symmetric Glide.*

# POSITION VCG

## INSTRUMENTS/ EQUIPMENT REQUIRED

- Anesthesia Ring
- Topical Anesthetic
- Vacuum Centering Guide (VCG)
- Procedure Marker



### NOTE:

*Using sterile technique, saturate a microsponge pledget, an anesthesia ring, or equivalent, in topical anesthetic and place on the sclera outside the cornea for approximately one minute prior to placement of the VCG.*

### PRECAUTION:

**Remove the anesthesia ring prior to VCG application.**


The sterile tubing from the VCG should be oriented in such a way as to minimize undue stress on the VCG and tubing. Ensuring that there is no torsion on the VCG or tubing will provide the most appropriate fixation for the VCG. The VCG is oriented around the limbus and final placement is arranged after the Procedure Marker is inserted into the VCG. In most cases, if this technique is followed, the reticle of the Procedure Marker should fall very close to the corneal center mark. Fine adjustment is achieved with gentle raising of the Vacuum Centering Guide and reapplication. When the centration guide sight is properly centered on the center mark, suction is to be applied. When suction is applied, gentle retropulsion of the globe will help to ensure adequate fixation.

### PRECAUTION:

**Be sure to position the VCG port temporally to avoid the risk of losing a vacuum seal during dissection of the intrastromal tunnel.**

It is recommended that the vacuum start in the low setting. A low setting range of 400-500 mBar is recommended. Once a vacuum seal has been established, confirm that the VCG is properly positioned by checking centration. If the VCG is not properly positioned, release vacuum and repeat from the beginning of this step. If the VCG is properly positioned, switch the vacuum to the high setting. A high setting range of 600-667 mBar is recommended. It is recommended that the vacuum not exceed 750 mBar. Remove the Procedure Marker.

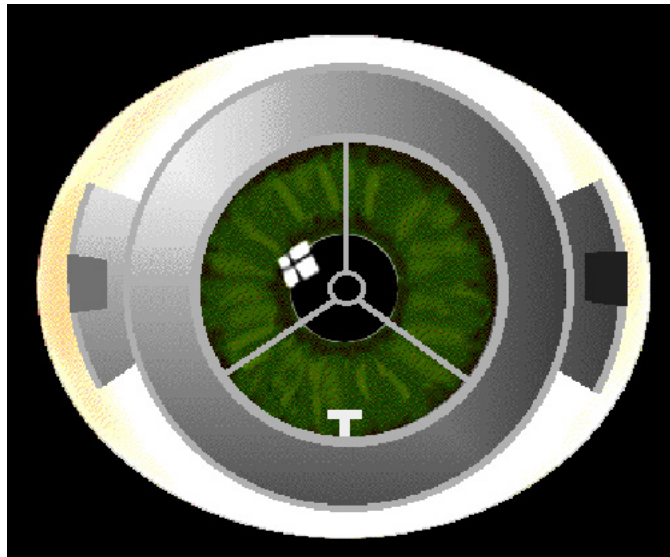
# POSITION VCG



**PRECAUTION:**

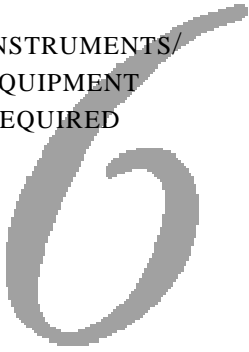
The VCG will remain in this position until both the clockwise and counterclockwise dissections are made.

The use of the Vacuum Centering Guide subjects the eye to increased intraocular pressure. **Continuous application of vacuum should be limited to 3 minutes or less and to no more than 750mBar.** If it is necessary to reapply the Vacuum Centering Guide, wait 5 minutes to allow normal vascular perfusion of the eye to occur before reestablishing suction.



# CREATE INTRASTROMAL TUNNELS

## INSTRUMENTS/ EQUIPMENT REQUIRED



- Symmetric Glide
- CW/CCW Corneal Separators
- Vacuum Centering Guide (VCG)



While maintaining the position of the VCG, insert the Clockwise (CW) Corneal Separator into the VCG. The Corneal Separator body should be rotated until the tip of the Corneal Separator is one to two clock hours from the incision site.

**Insert the Symmetric Glide (CW tip) vertically down into the incision until it contacts the bottom of the incision.** Insert the Symmetric Glide (CW tip) at least 1 mm into the pocket and rotate the Corneal Separator tip under the heel of the Symmetric Glide. Clockwise rotation of the Corneal Separator body will allow the tip to enter the pocket. Allow the Corneal Separator tip to enter the pocket approximately 1 mm to 2 mm, then stop. Remove the Symmetric Glide while leaving the Corneal Separator tip in position in the pocket.


**NOTE:** *Avoid starting the dissection while the Symmetric Glide is still in the intrastromal pocket.*

While holding the VCG vertically with one hand, rotate the Corneal Separator clockwise from the incision to create an intrastromal tunnel. Rotate the Corneal Separator clockwise until the hub of the Corneal Separator blade contacts the incision edge.

## PRECAUTIONS:

**Monitor the intrastromal tunnel dissection closely. If increasing resistance is felt, or if a corneal “tissue wave” is observed ahead of the Corneal Separator tip, the tunnel may be too shallow. Consider stopping the dissection and creating a deeper pocket and a deeper intrastromal tunnel.**

**Immediately discontinue the procedure in the event of an anterior chamber perforation.**



# CREATE INTRASTROMAL TUNNELS

6

Remove the clockwise Corneal Separator from the intrastromal tunnel by rotating the body counterclockwise until the tip exits the tunnel. Remove the Corneal Separator from the VCG.

While maintaining the position of the VCG, insert the Counterclockwise (CCW) Corneal Separator into the VCG. The Corneal Separator body should be rotated until the tip of the Corneal Separator is one to two clock hours from the incision site.

**Insert the Symmetric Glide (CCW tip) vertically down into the incision until it contacts the bottom of the incision.** Insert the Symmetric Glide (CCW tip) at least 1 mm into the pocket and rotate the Corneal Separator tip under the heel of the Symmetric Glide. Counterclockwise rotation of the Corneal Separator body will allow the tip to enter the pocket. Allow the Corneal Separator tip to enter the pocket underneath the Glide, advance it approximately 1 mm to 2 mm, then stop. Remove the Symmetric Glide while leaving the Corneal Separator tip in position in the pocket.

While holding the VCG vertically with one hand, rotate the Corneal Separator counterclockwise from the incision to create a second intrastromal tunnel. Rotate the Corneal Separator counterclockwise until the hub of the Corneal Separator blade contacts the incision edge.


NOTE: *Breakthrough of the two intrastromal tunnels to create a continuous 360° tunnel is not required.*

Remove the counterclockwise Corneal Separator from the intrastromal tunnel by rotating the body clockwise until the tip exits the tunnel. Remove the Corneal Separator from the VCG.

Release the vacuum and remove the VCG.

Remove any stromal debris from the incision site.

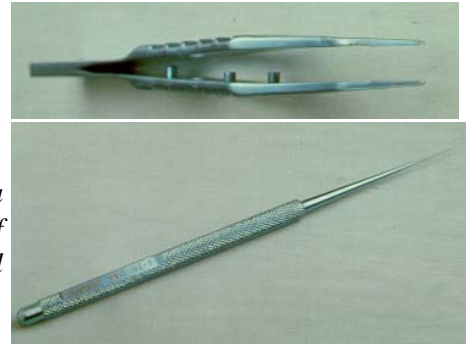
Thoroughly irrigate the incision area using balanced saline solution prior to placement of the Intacs Corneal Implants into the intrastromal tunnels.



# PLACE INTACS SEGMENTS

## INSTRUMENTS/ EQUIPMENT REQUIRED

- Intacs Forceps
- Sinskey Hook
- Intacs Carrier



### NOTE:

*Intacs Corneal Implants have a positioning hole located at each end of the segment to aid in surgical manipulation.*

## PLACEMENT OF THE FIRST INTACS SEGMENT

Using sterile technique, remove the Intacs Carrier from the sterile package assembly and place the Carrier in the sterile field. Stabilize the Carrier on a flat stable surface with the rounded end etched with “Intacs” facing up and pointing away from you. Slowly slide the cover of the Carrier back with your thumb until the first Intacs segment is exposed and the cover snaps into the first position. To prevent “pop-outs” it is recommended that you add 1-2 drops of a sterile, broad-spectrum antibiotic solution to the surface of the Intacs segment in the first “well” or slot of the Carrier. Using your free hand, grasp the Intacs Forceps so that the prongs of the Forceps point straight down. Lower the Forceps over the Carrier until the prongs contact the base of the cross-slot on each side of the Intacs segment. Gently grasp the segment at its mid-section (the inner and outer edges of the Intacs segment should nest in the slots of the Forceps) and lift the segment out of the Carrier slot.

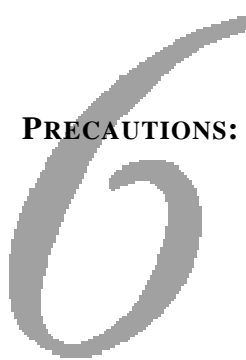
### NOTE:

*If an Intacs segment appears to be damaged, it should not be inserted. Contact Addition Technology regarding any product that is observed to be damaged.*

Introduce the first Intacs segment directly through the incision and into the prepared intrastromal tunnel. If it is necessary to reposition the segment within the Intacs Forceps, do so by placing the segment back into the Carrier, then regrasping the segment with the Forceps. Once the Intacs segment is advanced approximately halfway into the intrastromal tunnel, reposition the Forceps to complete the placement of the segment.



# PLACE INTACS SEGMENTS



## PRECAUTIONS:

**Intacs Corneal Implants should not be allowed to come into contact with iodine prior to insertion into the intrastromal tunnels.**

**Intacs Corneal Implants should not be placed on the surface of the cornea prior to insertion, as this may result in epithelial cell adherence or the introduction of bacteria into the intrastromal tunnels.**

Using the Intacs Forceps or a Sinsky Hook, manipulate the Intacs segment into the desired location within the intrastromal tunnel, aligning the outside edge of the segment with the ink markings created on the corneal surface by the Procedure Marker.

## NOTE:

*In the event that the ink marking fades, the Intacs segment ends should be placed approximately 3 mm apart and positioned symmetrically around the incision.*

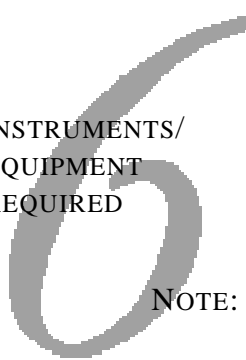
## PLACEMENT OF THE SECOND INTACS SEGMENT

Using the technique described above, add 1-2 drops of a sterile, broad-spectrum antibiotic solution to the surface of the Intacs segment in the second “well” or slot of the Carrier, remove the second Intacs segment from the Carrier and place the segment into the second intrastromal tunnel.

Remove any stromal debris from the incision area. Thoroughly irrigate the incision area with balanced saline solution.

# INCISION CLOSURE

## INSTRUMENTS/ EQUIPMENT REQUIRED



- 11-0 or 10-0 Ophthalmic Suture (11-0 recommended)

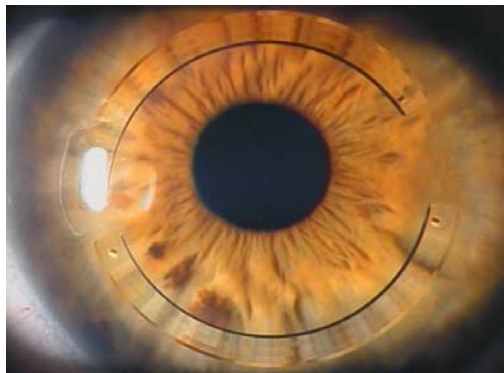
**NOTE:** *Prior to closing the incision, verify that each Intacs segment is properly positioned. If an Intacs segment is not properly positioned, remove the segment and repeat the insertion procedure to correct the positioning.*

Gently approximate the tissue edges to close the incision. If necessary, hydrate the incision to aid in approximating the tissue edges. If there is any difficulty approximating the incision edges, place one to two interrupted sutures. 11-0 or 10-0 nylon sutures, or equivalent, can be used to close the incision. 11-0 nylon suture is recommended. The suture depth should be to the level of the intrastromal pocket. Care should be taken to avoid microperforation by the suture needle. If two sutures are placed, the sutures should trisect from the superior and inferior aspects of the incision to insure apposition of the anterior edges of the incision. Bury the suture knots at the close of the procedure.

**NOTE:** *Hydration of the incision at the close of the procedure can be beneficial in helping to approximate the tissue edges of the incision.*

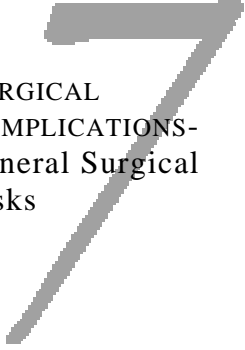
**PRECAUTIONS:** **The anterior incision edges must be apposed to prevent epithelial cells from entering the incision.**

**Care should be taken to ensure that tension across the sutures is evenly applied. Overtightening of the sutures should be avoided as this may induce astigmatism.**



# 7 Prevention & Management of Surgical Complications

# PREVENTION & MANAGEMENT OF SURGICAL COMPLICATIONS




## SURGICAL COMPLICATIONS- General Surgical Risks

As with any surgical procedure performed using anesthetic agents, the standard risks of anesthesia do exist. The anesthesia risks include allergic reactions, the remote chance of damage to the eye, medical complications or death. Risks to fetuses due to surgical anesthesia and other pharmacological agents used postoperatively are unknown. For this reason, pregnancy has been identified as a contraindication for this procedure. Though not directly related to Intacs Corneal Implants, all known general surgical risks should be discussed with patients prior to performing the surgical procedure.

## POTENTIAL AREAS FOR INTRAOPERATIVE COMPLICATIONS

- Corneal Marking
- Incision
- Pocketing Technique
- Application of Vacuum Centering Guide (VCG)
- Creating Intrastromal Tunnels
- Intacs Segment Placement
- Incision Closure

# PREVENTION & MANAGEMENT OF SURGICAL COMPLICATIONS



## Corneal Marking

Possible Complication	Cause	Impact or Result	Prevention	Management
<i>Center mark improperly located</i>	Did not locate geometric center	<ul style="list-style-type: none"> <li>• Decentered Intacs segment placement</li> <li>• Intacs segment placement &lt; 1mm from limbus</li> </ul>	Use 11mm Zone Marker	Re-mark geometric center
<i>Center mark fades prior to application of VCG</i>	<ul style="list-style-type: none"> <li>• Not enough pressure</li> <li>• Not enough ink</li> </ul>	Unable to properly center VCG	<ul style="list-style-type: none"> <li>• Indentation of epithelium with Sinskey Hook at geometric center</li> <li>• Application of ink to Sinskey Hook</li> </ul>	Re-mark geometric center
<i>Smearred markings</i>	Too much ink on Procedure Marker	Improper placement of incision or Intacs segments	Gentle application of ink to Procedure Marker	<ul style="list-style-type: none"> <li>• Maintain 1mm distance between incision and limbus</li> <li>• Position segment ends adjacent to the incision approximately 3 mm apart and symmetrically around the incision</li> </ul>

# PREVENTION & MANAGEMENT OF SURGICAL COMPLICATIONS

## 7

### Incision


Possible Complication	Cause	Impact or Result	Prevention	Management
<i>Shallow incision</i>	<ul style="list-style-type: none"> <li>• Knife set incorrectly</li> <li>• Inconsistent pressure during incision</li> </ul>	Shallow pocketing and/or shallow dissection that could lead to corneal surface perforation	<ul style="list-style-type: none"> <li>• Consider use of Micron Scope to verify knife setting</li> <li>• Verify knife setting is 68% of intraoperative pachometry reading &amp; no less than 450 microns at the incision site</li> <li>• “Push-Hold-Cut” Technique – apply firm, consistent pressure to footplate through entire incision; pause for 3-count after initial plunge</li> </ul>	<ul style="list-style-type: none"> <li>• Verify knife blade setting</li> <li>• Recut incision</li> </ul>
<i>Deep incision</i>	Knife set incorrectly	Anterior chamber perforation	Consider use of Micron Scope to verify knife setting	Stop the procedure immediately
<i>Incision too long</i>	Incision started or ended beyond incision mark	<ul style="list-style-type: none"> <li>• Incision &lt; 1mm from limbus could lead to limbal bleeding and postoperative neovascularization</li> <li>• Enlarged postoperative epithelial defect</li> </ul>	Only trace entire length of incision mark	<ul style="list-style-type: none"> <li>• Neosynepherine for limbal bleeding</li> <li>• Avoid extra manipulation of incision edges</li> </ul>
<i>Incision too short</i>	Incision started or ended prior to full length of incision mark	Symmetric Glide does not fit, cannot initiate dissection	Trace entire length of incision mark	Enlarge incision to full length of incision mark

# PREVENTION & MANAGEMENT OF SURGICAL COMPLICATIONS

## 7 Pocketing Technique

Possible Complication	Cause	Impact or Result	Prevention	Management
<i>Wound maceration</i>	<ul style="list-style-type: none"> <li>Stretching the wound, incision edges</li> <li>Using instruments on the incision edges</li> </ul>	<ul style="list-style-type: none"> <li>Epithelial trauma</li> <li>Postoperative induced astigmatism</li> </ul>	Avoid excessive manipulation of incision edges including stretching and use of instruments, such as forceps, on the incision edges	<ul style="list-style-type: none"> <li>Rehydrate incision</li> <li>Inspect incision site carefully to assess damage</li> <li>Consider not placing Intacs Corneal Implants</li> </ul>
<i>Shallow pockets</i>	Pocket initiated above base of incision	<ul style="list-style-type: none"> <li>Excessive resistance to intrastromal tunnel dissection</li> <li>Tissue wave in front of dissector</li> <li>Shallow dissection leading to corneal surface perforation</li> <li>Misaligned pockets leading to Intacs segment placement on different stromal levels</li> </ul>	<ul style="list-style-type: none"> <li>Initiate pockets at full depth of incision on both sides of incision</li> <li>Initiate pockets within a single intrastromal plane</li> </ul>	<ul style="list-style-type: none"> <li>Re-pocket at base of incision</li> <li>Re-pocket within a single intrastromal plane</li> </ul>
<i>Deep pockets</i>	Pocket initiated beneath base of incision	Anterior chamber perforation	<ul style="list-style-type: none"> <li>DO NOT insert Sinsky Hook or Pocketing Hook “tip-down” into the incision</li> <li>Always enter incision with blunt edges of instruments</li> </ul>	Stop the procedure immediately
<i>Narrow pockets</i>	Pockets do not extend the full length of the incision	Symmetric Glide does not fit in pockets	<ul style="list-style-type: none"> <li>Initiate pockets to be as wide as the full incision length and to extend the full length of the Pocketing Hook</li> <li>Always complete pocketing using the Pocketing Hook</li> </ul>	Re-pocket with Pocketing Hook

# PREVENTION & MANAGEMENT OF SURGICAL COMPLICATIONS



## Application of the Vacuum Centering Guide (VCG)

Possible Complication	Cause	Impact or Result	Prevention	Management
<i>Chemosis</i>	<ul style="list-style-type: none"> <li>• Draping technique</li> <li>• Use of local anesthesia</li> <li>• Use of pilocarpine</li> <li>• Prolonged manipulation/ exposure to VCG</li> </ul>	<ul style="list-style-type: none"> <li>• Loss of suction</li> <li>• Decentered or elongated tunnels</li> </ul>	<ul style="list-style-type: none"> <li>• Avoid traumatic draping</li> <li>• Avoid use of anesthetic injections</li> <li>• Avoid use of pilocarpine</li> <li>• Limit continuous application of VCG to 3 minutes; allow 5 minute “rest period” before reestablishing suction</li> </ul>	<ul style="list-style-type: none"> <li>• “Milk” chemosis with VCG</li> <li>• Gentle pressure to globe with VCG as suction is applied</li> <li>• If significant chemosis occurs, consider rescheduling the case</li> </ul>
<i>Subconjunctival hemorrhage</i>	<ul style="list-style-type: none"> <li>• Repeated application of VCG</li> <li>• Manipulation of conjunctiva using forceps</li> </ul>	Loss of suction	<ul style="list-style-type: none"> <li>• Limit continuous application of VCG to 3 minutes; allow 5 minute “rest period” before reestablishing suction</li> <li>• Avoid manipulating conjunctiva with forceps or other instruments</li> </ul>	<ul style="list-style-type: none"> <li>• Massage swollen conjunctival tissue with VCG</li> <li>• Gentle pressure to globe with VCG as suction is applied</li> <li>• If significant subconjunctival hemorrhage occurs, consider rescheduling the case</li> </ul>
<i>Inadequate suction / Break in suction leading to loss of centration</i>	<ul style="list-style-type: none"> <li>• Improper placement of VCG</li> <li>• Excessive downward pressure on Corneal Separator</li> <li>• Pressure to side of globe</li> </ul>	Elliptical intrastromal tunnel dissection leading to improper placement of Intacs Corneal Implants and possibly poor visual outcomes for the patient	<ul style="list-style-type: none"> <li>• After ensuring proper centration, apply gentle downward pressure as suction is initiated</li> <li>• Position VCG port temporarily to avoid suction break due to unexpected contact with tubing</li> <li>• DO NOT press down or raise up on Corneal Separator during tunnel dissection</li> </ul>	<ul style="list-style-type: none"> <li>• Always re-center using Procedure Marker</li> <li>• Allow 5 minute “rest period” before reestablishing suction</li> <li>• If unable to reestablish good suction, reschedule the case</li> </ul>

# PREVENTION & MANAGEMENT OF SURGICAL COMPLICATIONS

## 7

### Creating Intrastromal Tunnels


Possible Complication	Cause	Impact or Result	Prevention	Management
<i>Shallow dissection</i>	Shallow pocket	<ul style="list-style-type: none"> <li>Excessive resistance to intrastromal tunnel dissection</li> <li>Tissue wave in front of dissector</li> <li>Corneal surface perforation</li> </ul>	Ensure appropriate pocket depth before beginning dissections (see Pocketing Technique chart)	<ul style="list-style-type: none"> <li>Stop dissection, re-pocket at base of incision and re-tunnel</li> <li>Assess corneal surface perforation and either re-pocket and re-tunnel or reschedule the case</li> </ul>
<i>Deep dissection</i>	Deep or perforated pocket	<ul style="list-style-type: none"> <li>Anterior chamber perforation</li> </ul>	Ensure appropriate pocket depth before beginning dissections (see Pocketing Technique chart)	Stop the case immediately if an anterior chamber perforation occurs
<i>Misaligned, decentered or elliptical tunnels</i>	Decentration of VCG Loss of suction	<p>Poor visual outcomes for the patient as a result of the following:</p> <ul style="list-style-type: none"> <li>Elliptical or decentered tunnels</li> <li>Inferior or superior displacement of tunnels</li> <li>Nasal or temporal displacement of tunnels</li> </ul>	<ul style="list-style-type: none"> <li>Ensure proper centration of VCG before and after suction has been applied</li> <li>DO NOT push down or raise up on Corneal Separators during dissection</li> <li>Position VCG port temporally</li> <li>DO NOT continue dissection if suction is lost</li> </ul>	<ul style="list-style-type: none"> <li>Break suction and re-center VCG using Procedure Marker</li> <li>Attempt to re-tunnel</li> <li>Stop the procedure</li> </ul>

# PREVENTION & MANAGEMENT OF SURGICAL COMPLICATIONS

## Intacs Segment Placement

Possible Complication	Cause	Impact or Result	Prevention	Management
<i>Introduction of bacteria into intrastromal tunnel</i>	Intacs segments or surgical instruments contact corneal surface or lid margins prior to placement	Infection	DO NOT allow Intacs segments or surgical instruments to contact the corneal surface or lid margins prior to placement	Manage infections per instructions in Postoperative Healing chapter
<i>Elliptical placement of Intacs segments</i>	Improper placement of Intacs segments	Poor visual outcomes for the patient	“Push out and twist” when placing Intacs segments to ensure segment is aligned with outer edge of placement marking	Remove segment and reposition
<i>Intacs segments placed “upside-down”</i>	Improper alignment of segment cone angle	Difficult to insert segment	Verify segment position in Intacs Forceps prior to placement	Remove segment, verify position in Intacs Forceps and reposition
<i>Inadequate dissection</i>	Incomplete rotation of Corneal Separator	<ul style="list-style-type: none"> <li>• Proper positioning of segments cannot be achieved</li> <li>• Segments may migrate beneath incision</li> </ul>	Rotate Corneal Separator full length of blade until support spoke contacts the incision edge	Re-apply vacuum and re-tunnel to full length of Corneal Separator blade
<i>Smeared or faded segment position markings</i>	Too much or not enough ink on Procedure Marker	Proper position of segments difficult	Gentle application of ink to Procedure Marker (see Corneal Marking Chart)	Position segment ends adjacent to the incision approx. 3mm apart and symmetrically around the incision

# PREVENTION & MANAGEMENT OF SURGICAL COMPLICATIONS



## Incision Closure

Possible Complication	Cause	Impact or Result	Prevention	Management
<i>Tight closure</i>	Overtensioned suture(s)	Suture-induced astigmatism	<ul style="list-style-type: none"> <li>Hydrate incision to approximate edges</li> <li>11-0 interrupted suture recommended</li> <li>Make sure incision edges are apposed at the end of the procedure</li> <li>Avoid overtensioning suture(s)</li> </ul>	Remove suture if postoperative astigmatism is observed
<i>Loose closure</i>	<ul style="list-style-type: none"> <li>Loose or missing suture(s)</li> <li>Incision edges not properly approximated</li> </ul>	<ul style="list-style-type: none"> <li>Incision gape</li> <li>Epithelial cysts or plugs</li> </ul>	<ul style="list-style-type: none"> <li>Hydrate incision to approximate edges</li> <li>Suture, if necessary</li> </ul>	Place one or two interrupted 11-0 nylon suture(s)



# Postoperative Care & Management

# POSTOPERATIVE CARE & MANAGEMENT

IMMEDIATELY  
FOLLOWING  
SURGERY

THERAPEUTIC  
PROTOCOL  
(PATIENT  
INSTRUCTIONS)

POSTOP VISITS

POSTOP DAY 1

An antibiotic-steroid combination ointment or solution (0.1% dexamethasone/0.3% tobramycin or equivalent) is to be applied to the operative eye at the end of the procedure. Address any epithelial defect either through the use of lubricating drops for a small defect, or a bandage contact lens for a large defect. Evaluate the placement of the Intacs segments and incision closure using slit lamp examination. Shield the operative eye with a clear eye shield and ensure that the patient has copy of and understands their postoperative instructions.

- Postoperative medications (antibiotic-steroid combination solution [0.1% dexamethasone/0.3% tobramycin or equivalent]), qid x 1 week.
- Eye Shield at night for one week.
- Avoid RUBBING the eye as this may lead to segment migration or improper healing of the incision.
- Analgesic (acetaminophen, paracetamol or equivalent) for postoperative discomfort - other pain medication at surgeon's discretion.
- Typically patients experience mild to moderate discomfort for a few hours after surgery.
- Foreign body sensation or "scratchiness" is common during the immediate postoperative recovery period.
- Surgeon should be contacted for more severe pain.
- Symptoms for **infection**: dull, aching pain or discomfort, with or without photophobia, at any point in the postoperative period.
- During recovery, eyes may feel dry for the first 2 – 3 months. Expect vision to fluctuate during the first month.

A typical schedule of postoperative visits may be:

- 1 day
- 1 week
- 1 month
- 3 months
- 6 months

On the first postoperative day, the patient should have their visual acuity checked. The size of the epithelial defect should be noted. Suture knots should be buried and if they are not, an attempt to do so should be made.

# POSTOPERATIVE CARE & MANAGEMENT



## POSTOP DAY 2 THROUGH DAY 7

There may be mild subconjunctival hemorrhage and/or chemosis remaining from the Vacuum Centering Guide. Usually there is little to no intraocular inflammation. If a patient does not see an improvement in their vision, they should be advised that refractive surgery procedures typically require some recovery time and that their vision will most likely improve over time.

Therapy on the first day is centered around management of the epithelial defect and initiation of postoperative topical medications. The patient is advised that over the next three to six weeks the visual acuity should improve, but may fluctuate from day to day and in fact even during the course of the day. Any Day 1 astigmatism should be noted but no intervention should be initiated.

Ensure that the epithelial defect is healing in a normal fashion. The visual acuity at Day 3 is usually slightly less than on Day 1, secondary to superficial punctate keratitis from the topical medications and increased suture-induced astigmatism as the superior corneal edema in the region of the incision resolves.

The patient will generally be testing his own visual acuity in the operative eye between six and twenty times per day, and he will probably report diurnal fluctuating vision. If the epithelium has not yet healed, he may also still experience foreign body sensation.

By the end of the first postoperative week, the epithelium should be healed and any residual foreign body sensation should be resolved. Occasionally a “filament” will develop at the incision site causing foreign body sensation or pain. The filaments may be managed by either hypertonic saline drops, debridement or a bandage contact lens.

The use of a bandage contact lens to treat epithelial defects or filamentary keratitis should be monitored. Superficial neovascularization to the superior aspect of the incision may be aggravated by prolonged contact lens wear. The bandage contact lens should be discontinued as soon as the epithelial defect or filamentary keratitis resolves or at any time that limbal vascular buds form.

## POSTOP WEEK 1 THROUGH WEEK 4

The patient should have no ocular discomfort during this period. The eye should be quiet. Visual acuity typically will fluctuate from day to day and throughout the course of a day.

Suture-induced with-the-rule astigmatism may induce a “myopic shift” in the spherical equivalent since the concomitant flattening that is usually seen with suture-induced astigmatism may be blunted by the Intacs Corneal Implants.

# POSTOPERATIVE CARE & MANAGEMENT



POSTOP MONTH 1  
THROUGH MONTH 3

POSTOP MONTH 3  
AND BEYOND

Suture-induced astigmatism should be addressed early if the incision is healed and does not stain with fluorescein. Selective suture removal may be necessary if the induced astigmatism is greater than 1 diopter at two weeks. Typically, sutures are removed by four weeks. Clinical data suggests that with-the-rule astigmatism may be prolonged even after suture removal.

Between Month 3 and Month 6, begin assessing whether the patient is satisfied with their vision. Discuss options including replacement, if appropriate. Prior to considering replacement, perform a cycloplegic refraction and evaluate topography.

Between Month 3 and Month 6, the visual acuity should have stabilized. In the U.S. clinical trials for myopia, refractive stability was achieved by Month 6, as less than 1 diopter of shift in the spherical equivalent between subsequent visits occurred for most patients. Astigmatism should be reduced for most patients. High degrees of cylinder may continue to resolve over time. In general, late complications of Intacs Corneal Implants placement are rare. Patients should be followed on a normal routine basis after the Month 12 examination.



Intacs Corneal Implants  
Postoperative Findings &  
Classification System

# POSTOPERATIVE FINDINGS



## IMMEDIATELY FOLLOWING SURGERY (1 – 7 Days)

The observations reported for Intacs Corneal Implants for keratoconus are similar to those reported for the myopia indication. Postoperative healing findings will occur in one of three time frames: immediately following surgery (1 – 7 days), intermediate (1 – 4 weeks), or long term. Although no adverse events were reported for the clinical trial on the use of Intacs Corneal Implants for the treatment of keratoconus, it is important to know what can happen during the recovery and healing process, as well as how to deal with these clinical findings.

The following may be observed in the 1 to 7 day time frame immediately following surgery:

- ◆ Epithelial Defect
- ◆ Filamentary Keratitis
- ◆ Drug Toxicity / Allergy
- ◆ Infection
- ◆ Corneal Edema
- ◆ Suture Induced Astigmatism /Undercorrection

## POSTOPERATIVE EPITHELIAL DEFECT

Symptoms:     Decreased Visual Acuity  
                   Pain  
                   Foreign Body Sensation  
                   Photophobia

Typically, the epithelial defect at the end of the surgery measures 2 mm x 2 mm. In about half the cases, this epithelial defect is almost entirely resolved by the first postoperative day and in most cases completely resolved by Day 7. Since the peri-incisional epithelial defect is located under the upper lid, the patient usually does not have any discomfort. For patients who do have discomfort, a bandage contact lens can be worn until the defect heals. A bandage contact lens or mild patching can be utilized if the epithelial defect is larger than 2 mm x 2 mm.

### PRECAUTION:

**If pressure patching is attempted, beware of excessive pressure on the dome of the cornea that could cause movement or malpositioning of the segments.**

## FILAMENTARY KERATITIS

Symptoms:     Foreign Body Sensation  
                   Photophobia

Occasionally, with the healing of the epithelial defect a filamentary keratitis may develop. This usually consists of a single filament extending from the end of the incision. This may cause disproportionate discomfort to the patient and may be treated with debridement, hypertonic saline (5% sodium chloride) or a bandage contact lens.

# POSTOPERATIVE FINDINGS



## DRUG TOXICITY/ ALLERGY

Symptoms: Foreign Body Sensation  
Irritation

Findings: Superficial Punctate Keratitis  
Chemosis  
Lid edema and erythema

The presence of extensive chemosis should alert the surgeon to the possibility of an allergic reaction to the topical medications, unless significant trauma (i.e., difficulty with Vacuum Centering Guide (VCG) placement, or prolonged application of the VCG) was associated with the case. The presence of severe conjunctival chemosis in the early postoperative period should prompt a shift in topical medications.

## INFECTION

Symptoms: Significant ocular discomfort/pain  
Photophobia  
Decreased Vision

Findings: Infiltrate at incision  
Infiltrate in tunnel

Rapidly progressive infiltrates appearing in the first or second postoperative week may be infectious. The approach to presumed infectious infiltrates depends on the rapidity of progression. If the infiltrates are progressing in an indolent fashion, fortified topical antibiotic therapy and systemic antibiotic therapy may lead to resolution in a short period of time. Infiltrates that are progressing more rapidly, however, should be managed with aggressive topical fortified broad-spectrum antibiotic therapy and removal of the Intacs segments should be considered.

There were no infections reported at any time in the European keratoconus clinical trial. In the one case where an infectious infiltrate was identified in the U.S. myopia clinical trials, the organism cultured was *Staphylococcus epidermidis*. The presence of this organism suggests that it may have been introduced at the time of surgery, perhaps because of contact of the Intacs segments or instruments with the lid margin or the “lacrimal lake”. Prompt recognition, diagnosis and management of an infectious infiltrate can avert serious consequences and sequelae. The patient who had infectious lamellar infiltrates also developed ocular discomfort and photophobia. All patients who call or present with complaints of rapid onset of discomfort and photophobia should be seen as quickly as possible.

# POSTOPERATIVE FINDINGS

## CORNEAL EDEMA

Symptoms: Blurred vision

Findings: Peripheral Corneal Edema  
Central Corneal Edema

The presence of mild corneal edema as observed with other refractive procedures may be routinely expected to occur after the initial placement or removal/replacement of Intacs Corneal Implants. The frequency of peripheral and central corneal edema is rare, as is recurrent or extended corneal edema. The patient should be placed on topical corticosteroids or the dosage should be increased, as appropriate.

## SUTURE INDUCED ASTIGMATISM

Symptoms: Visual symptoms associated with induced astigmatism or undercorrection (glare, halos, double images & blurred vision)

Findings: “With-the-rule” astigmatism  
Undercorrection

If greater than or equal to 1.00 diopter of induced astigmatism is present, the probable source of the astigmatism should be identified. If the astigmatism appears to be related to over-tensioning of the incision sutures (i.e., “with-the-rule” astigmatism), this type of astigmatism typically diminishes over time.

Risk factors for the development of suture induced astigmatism include the use of 10-0 nylon, the use of more than one suture, tight suture closure, wound dehydration during surgery, and wound maceration/excess manipulation during surgery. **At any time after Day 7 where there is more than 1.00 D of “with-the-rule” astigmatism and sutures are still in place, the suture(s) should be removed.**

## SUTURE INDUCED ASTIGMATISM & UNDERCORRECTION

“With-the-rule” astigmatism does not couple. Steepening along the 90° meridian leads to additional steepening along the 180° meridian. This may result from the blunting of the typical flattening that occurs in the opposite meridian with suture-induced astigmatism. For example, a -2.00 + 2.00 x 90° refraction prior to suture removal will shift to plano after suture removal.

# POSTOPERATIVE FINDINGS

## INTERMEDIATE HEALING (1 – 4 WEEKS)



The following may be observed from 1 – 4 weeks following surgery:

- ◆ Induced “With-the-Rule” Astigmatism
- ◆ Induced “Against-the-Rule” Astigmatism
- ◆ Corneal Thinning
- ◆ Infiltrates
- ◆ Intacs Segment Displacement
- ◆ Large Pupil Issues
- ◆ Epithelial Plug

## INDUCED “WITH-THE- RULE” ASTIGMATISM

Symptoms:       Astigmatic Blur  
                      Double Vision

Findings:         Long incision with limbal encroachment  
                      Visible incision and suture scarring  
                      Elliptical decentration  
                      “With-the-rule” topographic changes

In the intermediate healing period, there have been instances where induced “with-the-rule” astigmatism has not resolved after suture removal. If sutures are too tight or left in place too long you may see with-the-rule astigmatism on a prolonged or even permanent basis. Two strategies have been used to address this issue: Topical corticosteroids may be used to carefully modulate overly aggressive wound healing during the initial postoperative period. A very small number of patients with astigmatism have been treated with very limited success by reincising the original incision and suturing loosely or leaving the incision unsutured for those patients who have corneas that healed aggressively. Available clinical data have not demonstrated consistent results for the latter strategy.

## INDUCED “AGAINST- THE-RULE” ASTIGMATISM

Symptoms:       Double Vision  
                      Astigmatic Blur

Findings:         “Against-the-rule” topographic changes  
                      Incision wound gape  
                      Cysts or epithelial plugs

Induced “against-the-rule” astigmatism may be caused by inadequate wound closure, wound trauma such as blunt force or eye rubbing, or flatter than average preoperative asphericity. Induced “against-the-rule” astigmatism can be managed by removing any epithelial cysts or plugs present, debriding the incision or by reapproximating the wound edges and resuturing the wound as appropriate.

# POSTOPERATIVE FINDINGS



## CORNEAL THINNING

Symptoms: Foreign Body Sensation

Findings: Epithelial breakdown/staining over Intacs segments  
Shallow placement of Intacs segments

Corneal thinning has been observed with shallow placement of the Intacs segments, typically when placed **less than 30% depth in the cornea**. Intacs segments should be removed as soon as shallow placement is observed. A new intrastromal tunnel can be made at the appropriate depth (68% of pachymetry reading) and the Intacs segments can then be repositioned. Early intervention is recommended to prevent corneal thinning.

## INFILTRATES

There are two types of infiltrates; sterile and infectious. Refer to the section on Infections for treatment of infectious infiltrates. Sterile infiltrates, when noted, are usually observed between Day 14 and Week 6 postoperatively.

Symptoms: Redness  
Photophobia

Findings: Focal whitish infiltrate  
Iritis  
Epithelial streaming

Possible causes for sterile infiltrates include poor wound healing, incomplete wound closure, presence of a foreign body (i.e., stromal debris, fiber, etc.) inadequate steroid dosing, and some form of mechanical trauma. Sterile infiltrates can be managed with combined antibiotic/steroid treatment or may be self-resolving over time.

## INTACS SEGMENT DISPLACEMENT

Intacs segment displacement may be either vertical or lateral.

Symptoms: Glare  
(*Vertical*) Starbursting  
Halo  
Variable Visual Acuity

Findings: Inferior/Superior placement  
Irregular astigmatism

# POSTOPERATIVE FINDINGS



Symptoms:            Glare  
(*Lateral*)            Starbursting  
                              Halo  
                              Variable visual acuity

Findings:            Mismatch of pupil to surgical centration  
                              Irregular topography  
                              Irregular astigmatism

Possible causes for vertical decentration include inadequate centration mark during surgery, incomplete tunnel dissection, incomplete advancement of the Intacs segments, aggressive eye rubbing by the patient, or segment movement within the intrastromal tunnel. Vertical decentration can be managed by removing the Intacs segments and replacing them by properly aligning on the pupillary center.

Possible causes for lateral decentration include decentered intrastromal tunnel, poor VCG placement or loss of suction during surgery, aggressive eye rubbing by the patient, oversized pocket adjacent to the incision or segment movement within the intrastromal tunnel. Lateral decentration can be managed by removing the Intacs segments and replacing them after properly aligning on the pupillary center.

## LARGE PUPIL ISSUES

Symptoms:            Patient sees edge of Intacs segments  
                              Glare  
                              Starbursting

Findings:            Large pupil in dark environment  
                              Mismatch of pupil to surgical centration

Possible causes for postoperative issues for patients with large pupils ( $\geq 7.0$  mm dilated pupil diameter) include poor initial patient selection, poor Intacs segment placement, decentered intrastromal tunnel or segment movement within the intrastromal tunnel. Large pupil symptoms can be managed by better initial patient selection, removal of the Intacs segments, repositioning of the Intacs segments or in some cases the symptoms may resolve over time.

## EPITHELIAL PLUG FORMATION IN INCISION

If an epithelial plug forms in the incision, the incision sutures (if present) should be removed and the incision area debrided and resutured. It is recommended that intervention occur as soon as possible after the observation is made. The patient should be followed closely to ensure adequate incision closure.

# POSTOPERATIVE FINDINGS



## OTHER INTERMEDIATE TO LATE FINDINGS

The following have been observed during the intermediate to late healing period:

- ◆ Positioning Hole Deposits
- ◆ Intrastromal Tunnel Deposits
- ◆ Pannus
- ◆ Deep Neovascularization
- ◆ Undercorrection / Overcorrection

## POSITIONING HOLE DEPOSITS

Positioning hole deposits usually appear between 3 to 6 weeks postoperatively. Two small positioning holes are located at each end of an Intacs segment to aid in surgical manipulation. These holes may fill with an opalescent substance which has been documented on a limited basis as being proteoglycan, collagen and keratocytes. The accumulation of material within the positioning holes is a normal finding and is nonprogressive and inconsequential from a clinical standpoint.

## INTRASTROMAL TUNNEL DEPOSITS

Intrastromal tunnel deposits generally appear between 3 to 12 months postoperatively. Intrastromal tunnel deposits were observed in 68% of the patients in the U.S. Phase III myopia clinical trial at the Month 12 exam.

These deposits remain confined to the intrastromal tunnel and do not spread centrally into the visual axis. In rare cases, the deposits have been progressive leading to confluent accumulations of opalescent material limited entirely to the dissected intrastromal tunnel. In these rare cases, the deposits may accumulate to the point that they are visible to the naked eye.

The specific origin and etiology of the deposits have not yet been conclusively established. The prevalence and levels of deposits remained stable from the Month 6 to the Month 12 exams. In all cases, the deposits were confined to the intrastromal tunnel with no visual consequence.

## PANNUS AND DEEP NEOVASCULARIZATION

Risk factors for the development of pannus include prior contact lens wear, preoperative pannus, incision extending to the limbal vessels during surgery, wound healing issues and loose sutures. Topical corticosteroids may be used to stop vessel growth once present. Advanced vessel growth which does not respond to topical corticosteroids may require laser therapy to impede deep vessel growth.

# POSTOPERATIVE FINDINGS

## UNDERCORRECTION/ OVERCORRECTION

If a patient is not satisfied with the correction achieved or the outcome of the Intacs procedure, the patient may elect to have the Intacs segments replaced with thinner or thicker segments (depending on the residual refractive error). Sufficient data are not currently available to determine the efficacy of exchanging Intacs segments. Alternatively, the Intacs segments may be removed and the patient's refraction returns to preoperative levels by three months following removal, in most instances (see Chapter 10, "Intacs Corneal Implants Removal and Replacement Procedure").

## INTACS CLASSIFICATION SYSTEM FOR POSTOPERATIVE FINDINGS

The Intacs classification system has been developed to aid in communicating findings among surgeons and between surgeons and optometrists who are providing postoperative care for Intacs patients. This classification system provides a "common language" for describing and communicating postoperative findings by assigning "grades" to findings in the following categories:

- ◆ Incision Healing
- ◆ Segment Positioning
- ◆ Intrastromal Tunnel Haze
- ◆ Intrastromal Tunnel Deposits

## INCISION HEALING

The initial incision created for Intacs Corneal Implants placement can heal postoperatively in three different ways. It can heal too tightly, too loosely, or normally and is graded as follows:


Grade	Description
+2	Tight, prominent incision line with surrounding diffuse white fibrotic tissue
+1	Tight with minimal fibrosis
<b>0</b>	<b>Normal healing, similar to RK incision</b>
-1	Slight gape, cysts or plugs may be present
-2	Obvious gape, cysts or plugs may be present

A normal healing response is given a grade of "0" for adequate wound closure with no effect on vision. The clinical appearance of this normal finding is similar to a small and clean RK incision. It is superior, with clean edges. An incision which closes tighter than normal is given a grade of "+1" or "+2", depending on its severity. A grade "+1" incision will be observed as tight with minimal fibrosis. A "+2" incision will be a tight prominent incision line with surrounding diffuse, white, fibrotic tissue and may induce astigmatism. As early as the one-week postoperative visit, 1.00 D of astigmatism or more should be addressed. If a suture is present, it should be removed. This simple step usually reverses the induced astigmatism, if performed early enough.

# POSTOPERATIVE FINDINGS

# 9

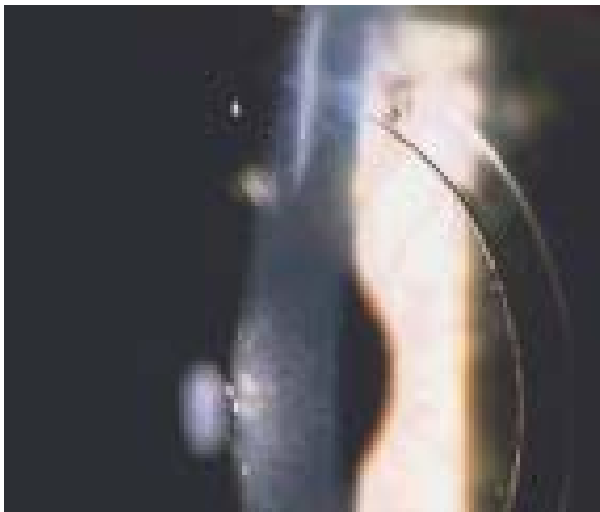GRADE 0: NORMAL INCISION HEALING



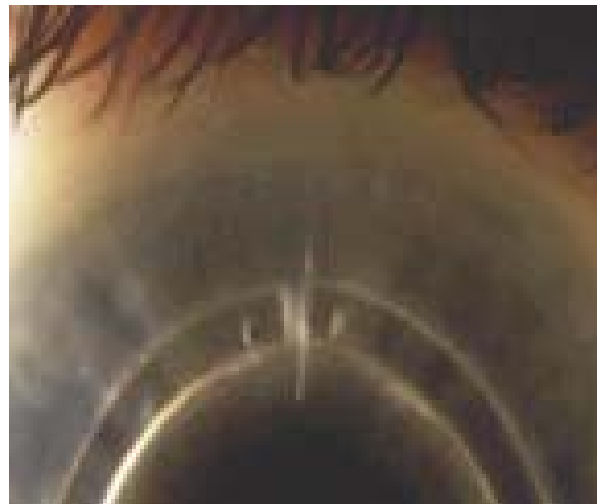
GRADE +1: TIGHT



GRADE +2: TIGHT



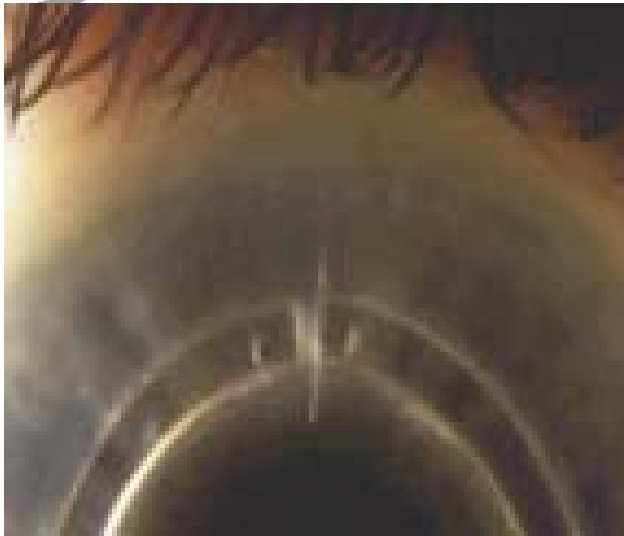GRADE -1: GAPE



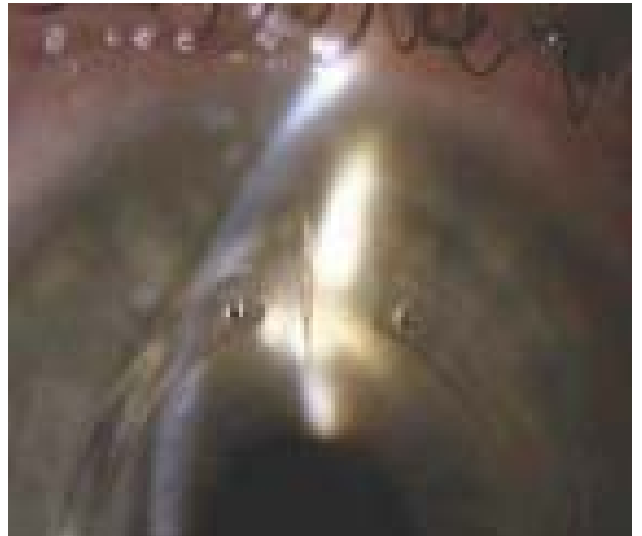# POSTOPERATIVE FINDINGS

9

GRADE -1: GAPE



GRADE -2: GAPE WITH CYST



GRADE -2: GAPE WITH CYST



# POSTOPERATIVE FINDINGS



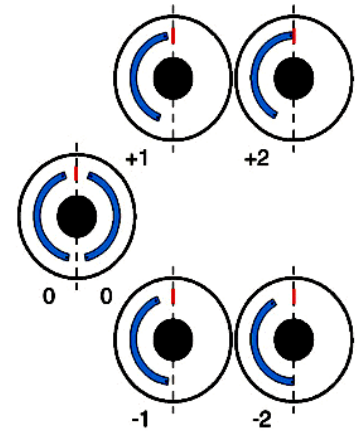
## INTACS POSITIONING

A loose healing response will appear as a gape in the incision. The incision is epithelialized, but the edges appear drawn apart and in some cases may be filled with epithelial plugs or cysts. A grade of “-2” is given when the incision area has obvious wound gape with or without epithelial plugs or cysts. A grade of “-1” has less obvious gape but not clean and even like a grade “0” incision.

Positioning grades for Intacs Corneal Implants are based on each segment’s position relative to the incision.

Grade	Description
+2	Underneath or congruent to incision site
+1	Shifted superiorly but not congruent to incision site
0	<b>Located 1 – 1.5 mm from incision site, segments 2 – 3 mm apart</b>
-1	Slight inferior displacement
-2	Significant inferior displacement, segments touch inferiorly

In the vertical or horizontal orientation, the end of the Intacs segments are located approximately 2-3 mm apart (with segment ends adjacent to the incision farther apart than segment ends 180° away from the incision) is given a grade of “0”. If the segments are in a more inferior or temporal position, a grade of “-1” or “-2” is given. Each Intacs segment should be graded separately. In addition, please be sure to indicate the placement of the respective Intacs segments relative to the incision [Nasal (N) vs. Temporal (T); Superior (S) vs. Inferior (I)]. If the segments are touching at the ends 180° away from the incision, a grade of “-2” and “-2” is given for the two segments. “Segment touch” 180° away from the incision is generally clinically inconsequential unless the segments ends overlap. Overlapping segment ends should be repositioned immediately. Slight segment displacement is graded as “-1”. Contrary to low segment displacement is high segment displacement. Slight displacement towards the incision is “+1” and significant displacement/movement is “+2”. In most circumstances Intacs segment displacement is asymptomatic. However, “+2” displacement could prevent proper incisional wound healing and could lead to deep vessel formation, stromal thinning, or even a corneal melt and infection in the incision area.

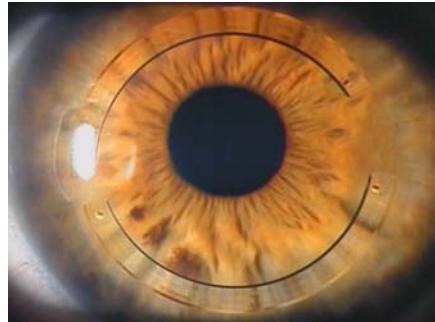


*Examples of superior incision placement are shown here for purposes of illustration. The same principles apply to horizontal orientation.*

# POSTOPERATIVE FINDINGS

9

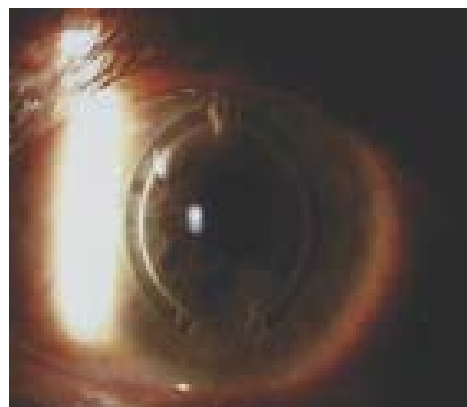
GRADE 0,0: GOOD POSITIONING



GRADE -2, -2: INFERIOR ENDS TOUCHING



GRADE +2, +2: SEGMENT UNDER INCISION



---

## INTRASTROMAL TUNNEL HAZE

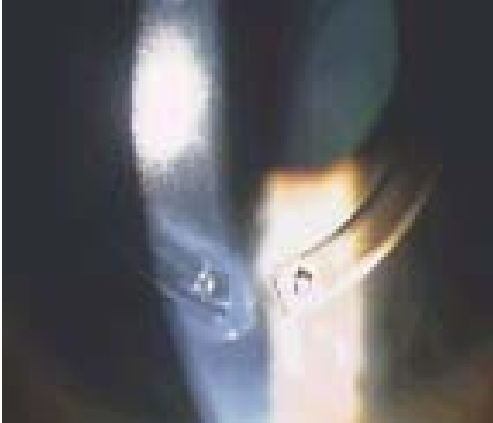The intrastromal tunnels are literally the remaining space created by the Corneal Separators in the periphery of the cornea that is not occupied by the Intacs Corneal Implants. Haze is evident in all patients at some point in their postoperative management, usually beginning in the first month, and has been shown to have no clinical sequelae. Intrastromal tunnel haze can be graded, using a slit-lamp, on a 0 to 4-point scale depending on its severity.

# POSTOPERATIVE FINDINGS

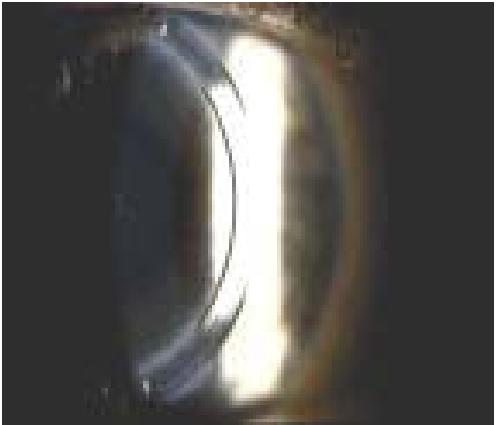GRADE 1: MILD LOSS OF STROMA  
TRANSPARENCY



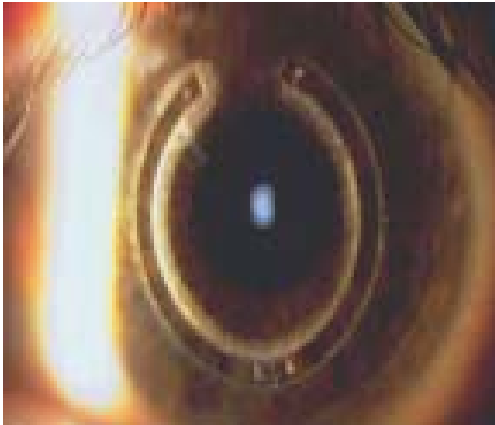GRADE 2: MODERATE LOSS OF STROMA  
TRANSPARENCY



GRADE 3: MODERATE TO HEAVY,  
HAZE NOTED ABOVE SEGMENT



GRADE 4: HEAVY LOSS OF TRANSPARENCY,  
NO IRIS DETAIL VISIBLE



GRADE 4: HEAVY LOSS OF  
TRANSPARENCY, NO IRIS DETAIL VISIBLE



# POSTOPERATIVE FINDINGS



## INTRASTROMAL TUNNEL DEPOSITS

Grade	Description
0	Clear cornea
1	<u>Mild</u> loss of stromal transparency
2	<u>Moderate</u> loss of stromal transparency
3	Moderate to <u>heavy</u> loss of transparency, haze noted <u>above segment</u>
4	Heavy loss of transparency, surrounds segment, <u>no iris detail</u> visible

A grade of “0” is no haze and crystal clear intrastromal tunnels. One cannot distinguish the intrastromal tunnel from the remaining cornea. A grade of “1” is translucent haze or mild loss of stromal transparency. The haze is present and noted on slit lamp examination but is translucent and may be segmental or only along certain areas of the Intacs segments. Underlying structures are visible although some cloudiness can be readily seen with diffuse illumination. A grade of “2” is moderate loss of stromal transparency, and usually is visible along the entire length of the segment. Underlying structures are slightly obscured with diffuse illumination. Intrastromal tunnel haze grade “3” is moderate to heavy loss of transparency, with visible involvement of the stroma anterior and posterior to the Intacs segments. The underlying structures are difficult to see. Grade “4” haze is heavy loss of transparency and completely surrounds the Intacs segments. No iris detail is visible. Intrastromal tunnel haze is relatively uniform.

Deposits are characteristically opaque, white or yellowish in color, on the inner and outer aspects of the intrastromal tunnel adjacent to the Intacs segments. These usually appear between the 3 and 12 months postoperatively and for the most part are noninflammatory and nonprogressive. These deposits are thought to be expelled from stromal keratocytes in an attempt to fill in the empty stromal spaces. These deposits remain confined to the intrastromal tunnel and do not spread centrally into the visual axis. Intrastromal tunnel deposits can be graded, using a slit-lamp, on a 0 to 4 scale depending on its severity.

Grade	Description
0	<u>Clear to trace appearance</u>
1	<u>Isolated</u> deposits throughout tunnel
2	<u>Diffuse</u> deposits that moderately obscure iris detail
3	Moderate deposits, more <u>confluent</u> , iris barely visible
4	<u>Fully confluent</u> deposits, no iris detail

Grade “0” is absent or barely detectable deposits. Grade “1” is isolated deposits located throughout the intrastromal tunnel. Grade “2” is more diffuse deposits with underlying structures being moderately obscured. Grade “3” is moderate deposits which are more confluent in certain areas and underlying structures are barely visible. Grade “4” deposits are fully confluent completely obscuring iris detail and may involve entire intrastromal tunnel width. The clinician may note clock hours of deposit locations to follow changes.

# POSTOPERATIVE FINDINGS

GRADE 0: CLEAR TO TRACE



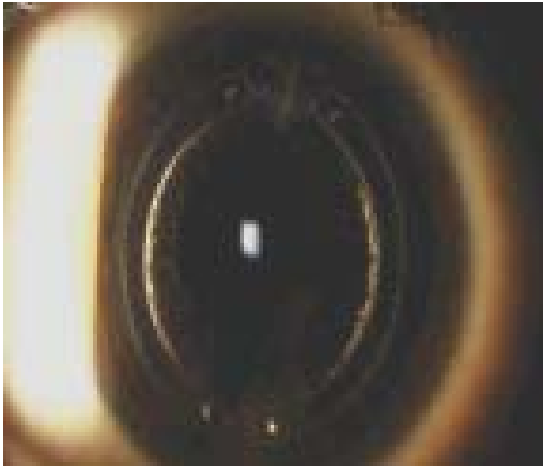GRADE 1: ISOLATED DEPOSITS



GRADE 2: DIFFUSE DEPOSITS



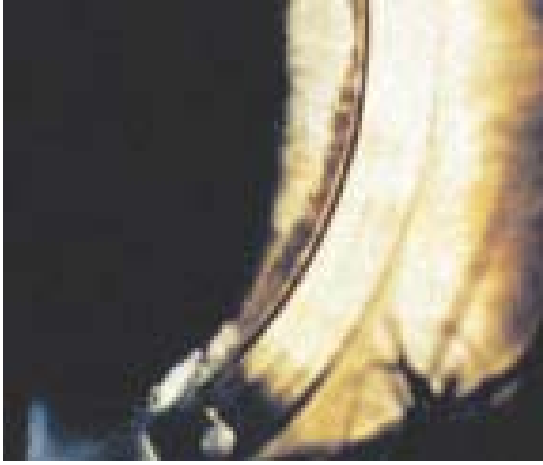GRADE 3: MODERATE, MORE CONFLUENT



GRADE 4: FULLY CONFLUENT

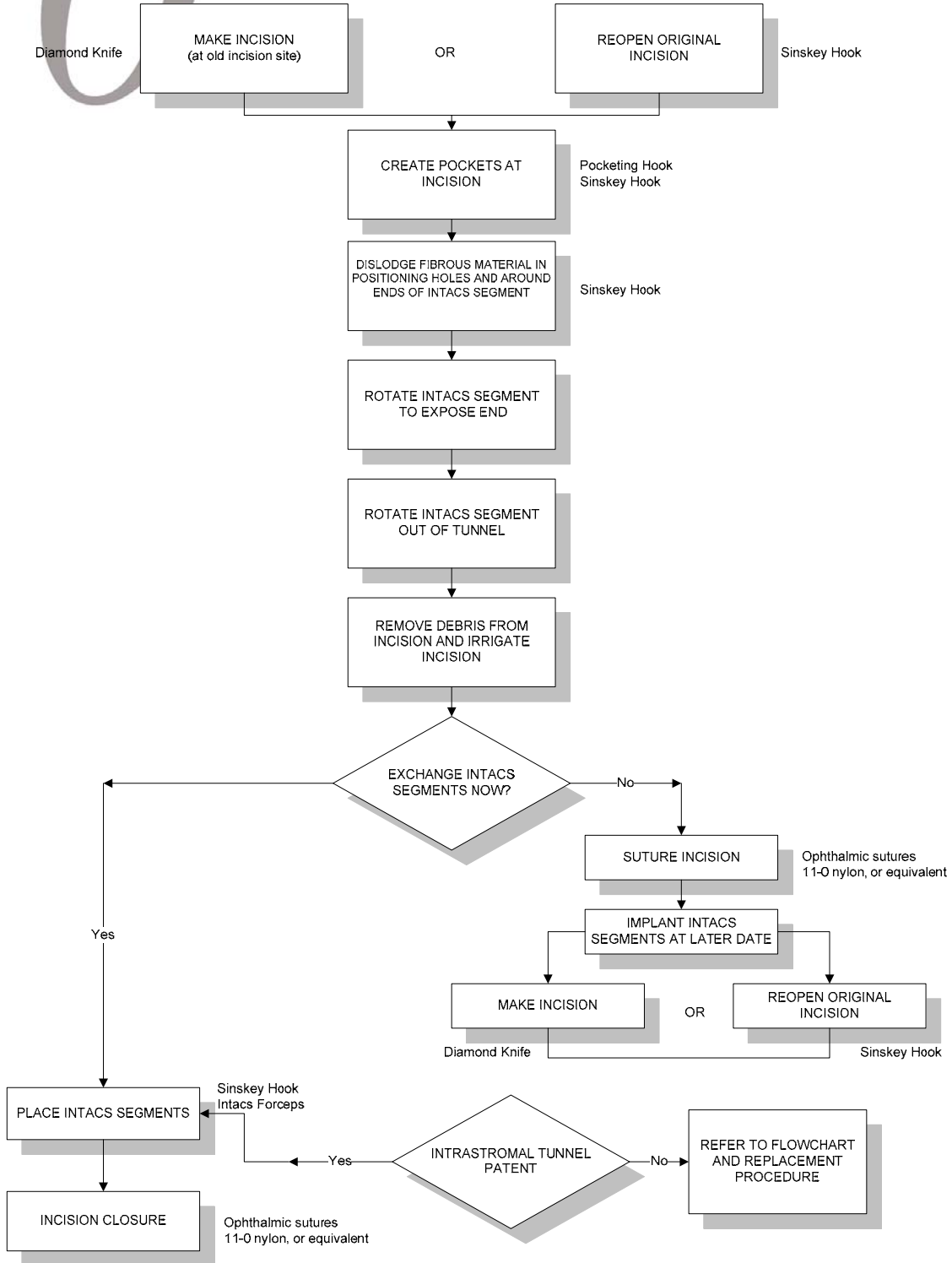


GRADE 4: FULLY CONFLUENT



# *10* Intacs Corneal Implants Removal and Replacement Procedure

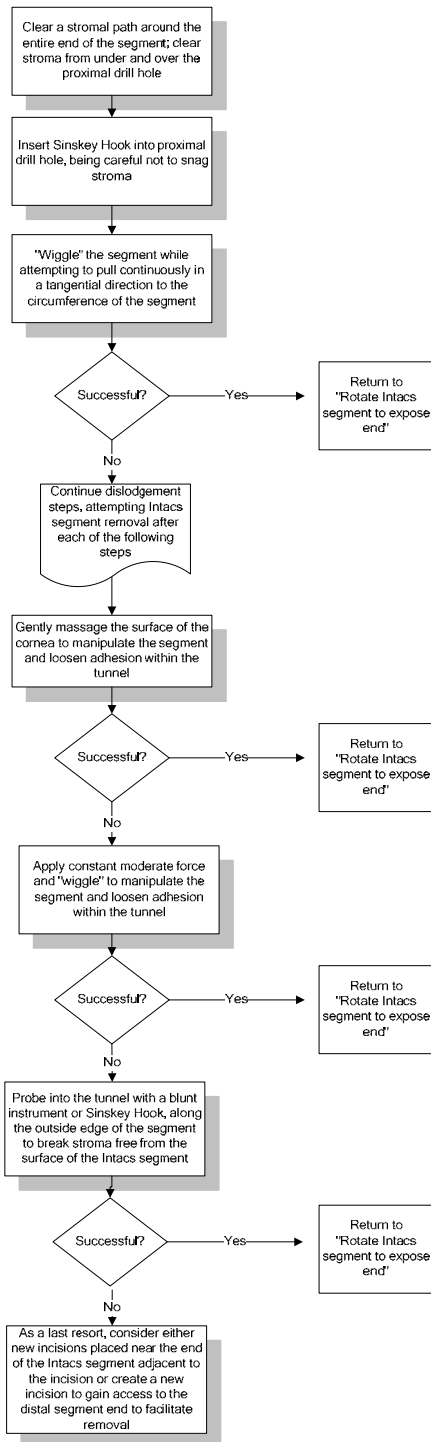
# INTACS CORNEAL IMPLANTS REMOVAL AND REPLACEMENT FLOWCHART



# INTACS CORNEAL IMPLANTS REMOVAL AND REPLACEMENT FLOWCHART

10

**Note:** D&K titanium Sinsky Hooks are recommended because of their stiffness. Stainless steel Sinsky Hooks will not be as effective.



# GUIDELINES FOR REMOVAL AND REPLACEMENT PROCEDURE

## 10 REMOVAL PROCEDURE REPLACEMENT PROCEDURE

Should a patient's vision correction needs change over time or if the patient experiences a clinically significant event, the surgeon may remove the Intacs Corneal Implants in a simple, brief removal procedure.

Patients who are not satisfied with the initial visual outcome should be encouraged to wait for a recommended period of time prior to having a replacement procedure performed. This will ensure that a stable refractive outcome has been achieved with the initial procedure. It is recommended that the following criteria be met before a patient is considered for a replacement procedure:

- ◆ It is recommended that patients have a **minimum of 3-6 months postoperative follow-up.**
- ◆ Dissatisfaction with current level of visual acuity or refractive outcome.
- ◆ Dissatisfaction with visual symptoms (i.e., glare, halos, fluctuating vision, double images, difficulty with night vision and decreased quality of vision).
- ◆ Cycloplegic refraction (spherical equivalent) greater than  $\pm 1.00$  D from the intended correction.
- ◆ Demonstrate refractive stability by manifest refraction spherical equivalent.

There may exist specific circumstances that warrant an early replacement of the Intacs Corneal Implants. These specific circumstances are:

- ◆ Intacs segments are damaged and the defect was not noted until after the surgical procedure is completed. If the Intacs segments are damaged, the surgeon should replace them at the earliest convenience.
- ◆ A patient is dissatisfied with the visual outcome, due to either an overcorrection or an undercorrection and is unable or refuses to wait for the recommended period.

# GUIDELINES FOR REMOVAL PROCEDURE

## 10

### PREOPERATIVE MEDICATION AND ANESTHESIA

Refer to the Intacs Corneal Implants Removal and Replacement Procedure Flow Chart. For Intacs segments that have been in place for an extended period of time, it is important to have a good estimate of the product's depth in the cornea. A slit lamp exam should be performed to estimate the depth of the Intacs segments relative to the total corneal thickness. If optical pachometry is available, it should be used as well to determine segment depth. Ultrasonic pachometry should not be used over the Intacs segments to determine their depth, as it has been demonstrated that ultrasound produces an inaccurate response when reflected off the Intacs segments.

Any preoperative medication will be ordered by the surgeon and/or the anesthesiologist. The recommended medication and treatment regimen for this procedure is outlined in Chapter 5.

Topical anesthesia, oral conscious sedation with topical anesthesia or local anesthesia is recommended for this procedure, based on the individual preferences of the surgeon and the patient.

### SURGICAL PREPARATION

Povidone-iodine scrubs and/or paint should be used for sterile preparation of the operative field. In the event of patient allergy to povidone-iodine, alternate scrub solutions may be used.

Care must be taken to avoid manipulating or irritating the patient's conjunctiva during the preoperative preparations.

Apply iodine solution (povidone-iodine 5% solution, dilute with sterile balanced salt solution 1:1 for a 2.5% solution) to the cul-de-sac to minimize the introduction of microorganisms into the incision or the intrastromal tunnel. Use a bulb syringe to introduce the solution to the cul-de-sac. Leave in place for two minutes and thoroughly flush with sterile balanced salt solution.

Intacs surgery should be performed in a lint-free environment. No gauze or other material with cotton fibers should be used in the sterile field. It is also recommended that the surgeon, surgical assistant and/or scrub nurse wear talc-free gloves.

Standard ophthalmic draping procedure should be followed. The use of a fenestrated plastic eye drape is recommended. Completely isolate the eyelashes from the surgical field per the recommendations provided in Chapter 5.

A wire lid speculum should be inserted for adequate lid separation.

NOTE: *Avoid overtightening of the wire lid speculum.*

# GUIDELINES FOR REMOVAL PROCEDURE

## 10

Flush the surface of the cornea with balanced saline solution to keep the cornea adequately hydrated throughout the procedure.

Set an adjustable-depth diamond knife to a setting that corresponds to the Intacs segments depth estimated during slit lamp examination and/or optical pachometry. Make a single cut-down incision, approximately 1.2 mm in length, (the incision may be at or very near the original entry incision) through the epithelium and stroma down to the level of the Intacs segments. Additionally, the incision should be placed approximately 1 mm away from any vascularization in the limbal region.

For Intacs segments that have been placed for a short time, the surgeon may elect to reopen the original entry incision to full depth with a Sinskey Hook or other similar instrument.

Using a Pocketing Hook, Sinskey Hook or similar instrument, re-pocket to expose the original tunnel to the proximal end of the Intacs segments.

NOTE: *D&K titanium Sinskey Hooks are recommended because of their stiffness. Stainless steel Sinskey Hooks will not be as effective for removing Intacs segments.*

Using a Sinskey Hook, clear a path around the entire end of the Intacs segment and break free any fibrous ingrowth that may have occurred by running the Sinskey Hook over and under the positioning holes.

Insert the Sinskey Hook into the proximal positioning hole, being careful not to snag stroma.

“Wiggle” the segment while attempting to pull continuously in a tangential direction to the circumference of the Intacs segment.

### Suggestions for Problematic Removal Cases:

(Try to remove the Intacs segment after each suggestion)

- Gently massage the surface of the cornea to manipulate the segment and loosen adhesion within the tunnel.
- Apply constant moderate force and “wiggle” to manipulate the segment and loosen adhesion within the tunnel.
- Probe into the tunnel with a blunt instrument or Sinskey Hook, along the outside edge of the segment, to break stroma free from segment’s surface.
- As a last resort, consider creating a new incision placed either near the end of the Intacs segment adjacent to the original incision or near the distal segment end to facilitate removal.

# GUIDELINES FOR REMOVAL PROCEDURE

# 10

NOTE:

*Placement of new incisions proximal to the original incision prohibits an Intacs exchange procedure as the Intacs segments will lie near the new incisions and this may create wound-healing issues.*

Rotate the Intacs segments within the tunnel to expose the end of the segment at the incision.

Grasp the segment with the Intacs Forceps and remove the segment by rotating it out through the reopened entry incision.

Verify that the Intacs segments and any debris are removed from the tunnel or incision site.

If Intacs segments are to be replaced at this time, proceed to the Replacement steps. If Intacs segments are to be replaced at a later date, proceed to the “Replacement at a later date” steps. If no replacement procedure is to be performed, continue with the next step.

**Gently approximate the tissue edges to close. If necessary, hydrate the incision to aid in approximating the tissue edges. If there is any difficulty approximating the incision edges, place one or two interrupted sutures. 11-0 nylon sutures, or equivalent, can be used to close the incision. A 11-0 nylon suture is recommended. The suture depth should be to the level of the intrastromal pocket. Care should be taken to avoid microperforation by the suture needle. If two sutures are placed, the sutures should trisect the incision line from the superior and inferior aspects of the incision to insure apposition of the anterior edges of the incision.**

**The anterior incision edges must be apposed to prevent epithelial cells from entering the incision. Care should be taken to ensure that tension across the sutures is evenly applied, however overtightening of the sutures should be avoided as this may induce astigmatism.**

Continue with Postoperative Care as described in Chapter 8.

# GUIDELINES FOR INTACS CORNEAL IMPLANT REPLACEMENT PROCEDURE - IMMEDIATELY FOLLOWING A REMOVAL PROCEDURE

# 10

Remove any debris from the incision site.

Thoroughly irrigate the incision area using balanced salt solution prior to inserting each segment into the intrastromal tunnel.

The leading end of each new Intacs segment is fed into the intrastromal tunnel from the incision. One segment is rotated clockwise and the second segment is rotated counterclockwise, if appropriate.

NOTE: *The Intacs segments have an anterior/posterior orientation. The segment should be placed in the stroma concave side down, such that the cone angle of the segment is most closely matched with the curvature of the patient's cornea.*

Using Intacs Forceps or a Sinsky Hook, manipulate the Intacs segments into the desired location within the intrastromal tunnel. The segment ends adjacent to the incision should be placed approximately 3 mm apart and symmetrically positioned around the incision.

Remove any stromal debris from the incision area. Thoroughly irrigate the incision area with balanced salt solution.

**Gently approximate the tissue edges to close. If necessary, hydrate the incision to aid in approximating tissue edges. If there is any difficulty approximating the incision edges, place one or two interrupted sutures. 11-0 nylon sutures, or equivalent, can be used to close the incision. A 11-0 nylon suture is recommended. The suture depth should be to the level of the stromal pocket. Care should be taken to avoid microperforation by the suture needle. If two sutures are placed, the sutures should trisect the incision line from the superior and inferior aspects of the incision to insure apposition of the anterior edges of the incision.**

**The anterior incision edges must be apposed to prevent epithelial cells from entering the incision. Care should be taken to ensure that tension across the sutures is evenly applied, however overtightening of the sutures should be avoided as this may induce astigmatism.**

# GUIDELINES FOR IMPLANTING NEW INTACS CORNEAL IMPLANTS AT A LATER DATE

# 10

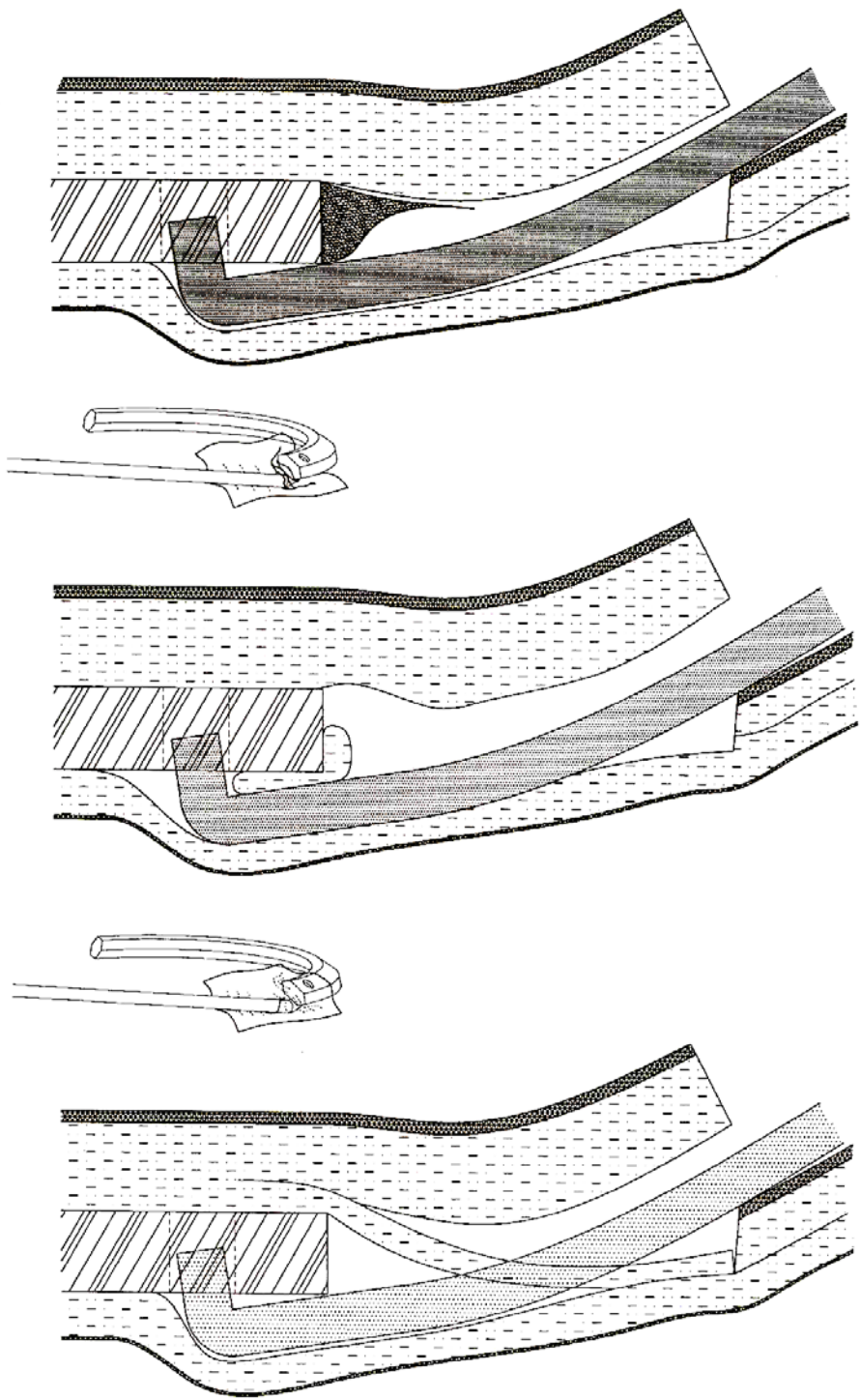
Determine if the intrastromal tunnel is patent.

If the tunnel is patent, follow Replacement Procedure as documented in this chapter.

If the tunnel is not patent, create new intrastromal tunnels following the steps outlined in Chapter 6, Intacs Corneal Implants Surgical Technique.

Continue with Postoperative Care as described in Chapter 8.

# REMOVAL PROCEDURE



# REMOVAL PROCEDURE

